

A rare urea cycle disorder in a neonate: N-acetylglutamate synthetase deficiency

Asburce Olgac, M.D.^a; Çiğdem S. Kasapkara, M.D.^a; Mustafa Kilic, M.D.^a; Betül Emine Derinkuyu, M.D.^b; Ebru Azapagasi, M.D.^c; Selman Kesici, M.D.^c; Gürsel Biberoglu, M.D.^d; Ahmet Ozyazici, M.D.^e; Meryem Karaca, M.D.^f; Johannes Haberle, M.D.^g

ABSTRACT

Urea cycle disorders (UCD), are genetically inherited diseases that may have a poor outcome due to profound hyperammonemia. We report the case of a baby girl diagnosed as N-acetylglutamate synthase (NAGS) deficiency. The patient was evaluated due to diminished sucking and hypotonicity. Physical examination showed hepatomegaly. Complete blood count, biochemical values and blood gas analyses were normal, acute phase reactants were negative. Further laboratory analyses showed no ketones in blood and highly elevated ammonia. Metabolic tests were inconclusive. Emergency treatment was initiated immediately and she was discharged on the 15th day of admission. NAGS deficiency was confirmed by DNA-analysis. She is now without any dietary restriction or other medication, except N-carbamylglutamate (NCG). NAGS deficiency is the only UCD which can be specifically and effectively treated by NCG. Early recognition of disease will lead to early treatment that may prohibit devastating effects of hyperammonemia.

Key words: urea cycle disorders, inborn, N-acetylglutamate synthase deficiency, hyperammonemia.

<http://dx.doi.org/10.5546/aap.2020.eng.e545>

To cite: Olgac A, Kasapkara CS, Kilic M, Emine Derinkuyu B, et al. A rare urea cycle disorder in a neonate: N-acetylglutamate synthetase deficiency. *Arch Argent Pediatr* 2020;118(6):e545-e548.

INTRODUCTION

Urea cycle disorders (UCD), caused by the deficiencies of enzymes or transporters involved in the urea cycle, are genetically inherited inborn errors of metabolism (IEM) that have variable clinical presentations. Severe deficiencies of enzymes are typically associated with profound hyperammonemia, presenting with poor feeding, vomiting, lethargy, tachypnea, convulsions, and coma, especially in the neonatal period. In milder deficiencies, catabolic circumstances such as illnesses or stress may trigger hyperammonemia and can present at any age. Neonatal UCDs are mostly misdiagnosed as neonatal sepsis. Children and adults with partial deficiencies can also develop neurological or psychiatric symptoms including headaches, behavioral changes, confusion, and cyclic vomiting.¹

N-acetylglutamate synthase (NAGS) is one of the enzymes involved in the urea cycle that catalyses the production of N-acetylglutamate (NAG) from glutamate and acetyl-CoA. NAGS deficiency is probably the rarest UCD, with just over 50 published cases worldwide.² It is most effectively treated with N-carbamylglutamate (NCG) that corrects hyperammonemia and support ureagenesis.³

We report the case of a neonate diagnosed as NAGS deficiency.

Case description

A baby girl born at term weighing 2500 grams was evaluated in an external clinic on the fifth postnatal day due to diminished sucking and hypotonicity. She was the first living child of consanguineous parents (first degree cousins) of Turkish origin. Their first child had died suddenly at the age of 2 days due to unknown etiology. Early neonatal sepsis was the suspected diagnosis in the present child and she was admitted to the newborn intensive care unit.

- Division of Pediatric Metabolism, Dr. Sami Ulus Maternity and Children's Health and Diseases Training and Research Hospital, Ankara, Turkey.
- Division of Pediatric Radiology, Dr. Sami Ulus Maternity and Children's Health and Diseases Training and Research Hospital, Ankara, Turkey.
- Pediatric Intensive Care Unit, Dr. Sami Ulus Maternity and Children's Health and Diseases Training and Research Hospital, Ankara, Turkey.
- Division of Pediatric Metabolism and Nutrition, Gazi University Hospital, Ankara, Turkey.
- Division of Neonatology, Dr. Sami Ulus Maternity and Children's Health and Diseases Training and Research Hospital, Ankara, Turkey.
- Division of Pediatric Metabolism, Harran University Hospital, Sanliurfa, Turkey.
- Division of Metabolism, University Children's Hospital, Zurich, Switzerland.

E-mail address:

Asburce Olgac, M.D.: mabolgac@yahoo.com

Funding: None.

Conflict of interest: None.

Received: 6-17-2020

Accepted: 7-13-2020

Complete blood count, routine biochemical values and blood gas analyses were normal, acute phase reactants were negative. She was hydrated intravenously and to exclude meningitis, lumbar puncture was performed that showed normal microscopic and biochemical cerebrospinal fluid (CSF) values. Parenteral antibiotics were initiated. Since her general condition did not improve after rehydration, further laboratory analyses were performed that showed no ketones in blood but highly elevated ammonia ($937 \mu\text{mol/L}$, normal value $<150 \mu\text{mol/L}$). With the suspicion of an inborn error of metabolism, she was referred to our center on the 10th postnatal day.

Upon admission, she was in poor condition and was ventilated. Her weight and height were within low-normal centiles. Physical examination showed hepatomegaly (liver was 4 cm palpable below the lower costal margin). Initial laboratory analyses showed hyperammonemia ($2404 \mu\text{mol/L}$) and abnormal blood coagulation parameters.

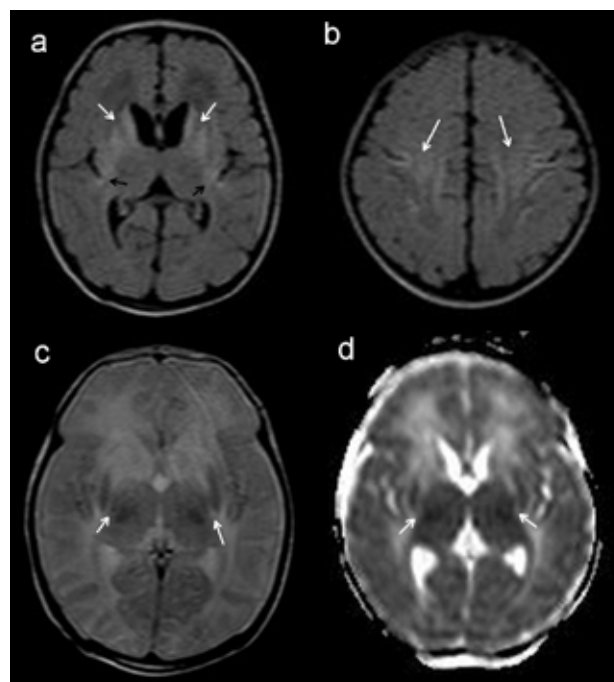
Ammonia lowering agents including intravenous sodium benzoate 250 mg/kg as a

bolus and NCG by nasogastric tube was initiated. Since the patient did not have a specific diagnosis, oral L-carnitine and biotin plus intramuscular hydroxycobalamin were administered according to the latest guidelines on treatment for hyperammonemia.³

Brain MRI was performed that showed increased signal intensity of the caudate nucleus and putamen and insular cortex bilaterally (Figure 1).

Metabolic tests performed showed a normal acylcarnitine profile in dried blood spot analysis. Amino acids in plasma showed slightly increased alanine ($496 \mu\text{mol/L}$; NR: 143-439), normal glutamine ($363 \mu\text{mol/L}$; NR: 246-1182) and arginine ($54 \mu\text{mol/L}$; NR: 12-133) and decreased citrulline ($2 \mu\text{mol/L}$; NR: 3-35). Urine amino acid analyses and urine organic acids were normal. Biotinidase activity was within normal limits. Thus, mainly a proximal UCD, either of NAGS or carbamoyl phosphate synthetase 1 (CPS1) deficiency, were suspected primarily due to inconclusive findings in acylcarnitine and amino acid analyses. She was discharged on the 15th day

FIGURE 1. Brain MRI, axial plane FLAIR sequence (a) demonstrates increased signal intensity of the caudate nucleus and putamen (white arrows) and insular cortex (black arrows) bilaterally. Note the signal abnormality is extending superiorly into the perirolandic regions (white arrows) and prefrontal cortex bilaterally (b). Axial plane T2-weighted MRI (c) shows T2 shortening of the putamen, globus pallidus and ventrolateral thalamus (white arrows) with decreased size. Axial apparent diffusion coefficient (d) magnetic resonance image shows restricted diffusion in the putamen and thalamus (white arrows) seen as dark signal



of admission with protein limited diet, sodium benzoate 250 mg/kg per day and NCG 50 mg/kg per day.

NAGS deficiency was confirmed by DNA-analysis, which identified a known homozygous missense c.1450T>C (p.Trp484arg) mutation in exon 6 of the *NAGS* gene. Parents were shown to be heterozygous carriers of the mutation.

After gradual decrease of the medical treatment except NCG (30 mg/kg per day), she is without any dietary restriction or other medication. She is now 1,5 years old with some degree of global retardation but improving milestones, without any further episodes of hyperammonemia since the initiation of NCG.

DISCUSSION

NAGS deficiency is the rarest UCD, accounting for 0,5-1 % of all UCDs, that may have serious effects on the neurological system of the newborn due to severe hyperammonemia depending on the duration and degree of hyperammonemia.¹⁻³ Prognosis is known to be unfavourable if ammonia levels exceed 1000 $\mu\text{mol/L}$.³ Differential diagnosis includes other IEMs (e.g. organic acidurias), and conditions that cause hyperammonemia (e.g. sepsis, liver failure, congenital infections, exogenous intoxications, certain drugs, porto-caval shunting, Reye syndrome, conditions with protein catabolism, and excessive nitrogen supply due to parenteral nutrition). Premature infants can have transient hyperammonemia due to ductus venosus shunting of portal blood.³

Due to the devastating effects of hyperammonemia, treatment including cessation of protein intake, continuous infusion of high dose parenteral glucose and nitrogen scavenger drugs should be started immediately. Drugs that can be used to treat hyperammonemia depending on the underlying etiology are nitrogen scavenger drugs (sodium benzoate, sodium phenylbutyrate, sodium phenylacetate), L-arginine and NCG. Another long term treatment option for UCDs is liver transplantation in selected patients. NCG is a synthetic drug and a structural analog of human NAG.³ Hyperammonemia due to NAGS deficiency can be effectively treated by NCG, and no dietary restriction may be needed, at least outside catabolic situations.^{4,5} NCG has been suggested to be added to the standard treatment protocol of hyperammonemia together with sodium benzoate, sodium phenylbutyrate and L-arginine.³

Genetic analysis is the gold standard for diagnosis of NAGS deficiency,³ since ordinary metabolic screening tests may be inconclusive. *NAGS* gene is located on chromosome 17 within band 17q21.31. At least 45 different mutations of *NAGS* gene have been described until now.^{2,6} Al Kaabi et al. has reviewed the clinical and molecular spectrum of 41 different *NAGS* mutations showing 60 % to be missense, 10 % nonsense, 20 % frameshift and 10 % splice site mutations.⁶ The mutation of our patient is a previously known missense mutation, that is known to cause neonatal hyperammonemic crises.^{2,5,7} Genetic diagnosis should be performed to confirm the disease and also to provide prenatal testing and preimplantation genetic diagnosis (PGD) for the future offsprings of parents.

Our patient is now 1.5 year old with delayed motor and mental milestones. Hyperammonemia treatment was started on a relatively late period (the 10th day of life) when the catastrophic effects of hyperammonemia should have already begun. Reigstad et al.,⁸ have reported a baby girl with severe hyperammonemia (2235 $\mu\text{mol/L}$) that turned out to be due to NAGS deficiency, in whom NCG was started on the 4th day of life that showed normal neurological outcome later on. In our patient, after the initiation of NCG, no more hyperammonemic episodes have been observed, and no dietary restriction is needed now. Although NCG has prevented further mental deterioration, our case is an example of the undesirable effects of hyperammonemia in case of delayed diagnosis and treatment, and we would like to emphasize the need of immediate assessment of hyperammonemia and initiation of emergency treatment with nitrogen scavenger drugs and NCG.

We would like emphasize the importance of metabolic screening (including ammonium levels) in ill neonates with septic findings. Pediatricians should be aware of the signs of intoxication type IEMs, since this type of metabolic disorders may be effectively treated with certain measures, if the diagnosis is made at the early time. A detailed history should be obtained from parents, especially the history of inbreeding and death of sibling should be questioned, since these items may suggest an underlying IEM. Family counselling should be assured for parents with an unexplained history of child death, since these parents may require PGD.

In conclusion, NAGS deficiency is the only

disorder within the urea cycle which can be specifically and effectively treated by NCG with no dietary restrictions. Early recognition of disease will lead to early treatment that may prohibit devastating effects of hyperammonemia and may affect disease outcome positively. ■

REFERENCES

1. Wijburg FA, Nassogne MC. Disorders of the urea cycle and related enzymes. In: Saudubray JM, van den Berghe G, Walter JH (Eds). *Inborn Metabolic Diseases*. Berlin Heidelberg: Springer; 2012:297-310.
2. Sancho-Vaello E, Marco-Marin C, Gougeard N, Fernández-Murga L, et al. Understanding N-acetyl-L-glutamate synthase deficiency: mutational spectrum, impact of clinical mutations on enzyme functionality, and structural considerations. *Hum Mutat*. 2016;37(7):679-94.
3. Häberle J, Boddaert N, Burlina A, Chakrapani A, et al. Suggested guidelines for the diagnosis and management of urea cycle disorders. *Orphanet J Rare Dis*. 2012;7:32.
4. Gessler P, Buchal P, Schwenk HU, Wermuth B. Favourable long-term outcome after immediate treatment of neonatal hyperammonemia due to N-acetylglutamate synthase deficiency. *Eur J Pediatr*. 2010;169(2):197-9.
5. Van Leynseele A, Jansen A, Goyens P, Martens G, et al. Early treatment of a child with NAGS deficiency using N-carbamyl glutamate results in a normal neurological outcome. *Eur J Pediatr*. 2014;173(12):1635-8.
6. Al Kaabi EH, El-Hattab AW. N-acetylglutamate synthase deficiency: Novel mutation associated with neonatal presentation and literature review of molecular and phenotypic spectra. *Mol Genet Metab Rep*. 2016;8:94-8.
7. Häberle J, Denecke J, Schmidt E, Koch HG. Diagnosis of N-acetylglutamate synthase deficiency by use of cultured fibroblasts and avoidance of nonsense-mediated mRNA decay. *J Inher Metab Dis*. 2003;26(6):601-5.
8. Reigstad H, Woldseth B, Häberle J. Normal neurological development during infancy despite massive hyperammonemia in early treated NAGS deficiency. *JIMD Rep*. 2017;37:45-7.