



Received for publication: February 11, 2019  
Accepted: April 17, 2019

## Case report

# Prenatal diagnosis and conservative management of complex meconium peritonitis: a case report

Gürcan Türkyılmaz<sup>1</sup>, Didar Kurt<sup>1</sup>, Tuğba Saraç Sivrikoz<sup>1</sup>, İbrahim Kalelioğlu<sup>1</sup>, Recep Has<sup>1</sup>, Atıl Yüksel<sup>1</sup>

<sup>1</sup>Istanbul University- Istanbul Faculty of Medicine, Department of Obstetrics and Gynecology, Istanbul, Turkey

### Abstract

Meconium peritonitis is a rare fetal disease due to the perforation of bowel in utero and sterile inflammatory reaction related to the extravasation of the meconium. Various classification systems have been published in the literature, and better outcomes have been seen in recent years with a survival rate of more than 90%. The prognosis of meconium peritonitis is more favorable when detected in utero rather than when the neonatal diagnosis is made.

Prenatal findings of meconium peritonitis in our case are meconium pseudocyst, polyhydramnios, and peritoneal calcifications. Although it was perceived as complex meconium peritonitis and was expected to require surgery in the postnatal period, it was managed conservatively. Probably, it did not need to undergo surgery because the perforation had occurred in mid-trimester and enough time has elapsed in the utero life to seal the perforation site and to decrease the size of the meconium pseudocyst. We cited a rare case of meconium peritonitis with a meconium pseudocyst in a fetus, which was managed conservatively and resolved spontaneously in the postnatal period.

### Keywords

: intraabdominal cyst, meconium peritonitis, prenatal peritoneal calcification, prenatal diagnosis, conservative therapeutic management

### Highlights

- ✓ Meconium peritonitis diagnosed prenatal differ from neonatal diagnosis by better prognosis and reduced mortality.
- ✓ Even in complex disease, the neonatal course might be encouraging and spontaneous recovery might be occurred.

**To cite this article:** Türkyılmaz G, Kurt D, Sivrikoz TS, Kalelioğlu İ, Has R, Yüksel A. Prenatal diagnosis and conservative management of complex meconium peritonitis: a case report. *J Clin Invest Surg.* 2019; 4(1): 48-52. DOI: 10.25083/2559.5555/4.1/48.52



\*Corresponding author: Gürcan Türkyılmaz, Istanbul University- Istanbul Faculty of Medicine, Department of Obstetrics and Gynecology, Istanbul, Turkey  
Email: [gurcanturkyilmaz@gmail.com](mailto:gurcanturkyilmaz@gmail.com)

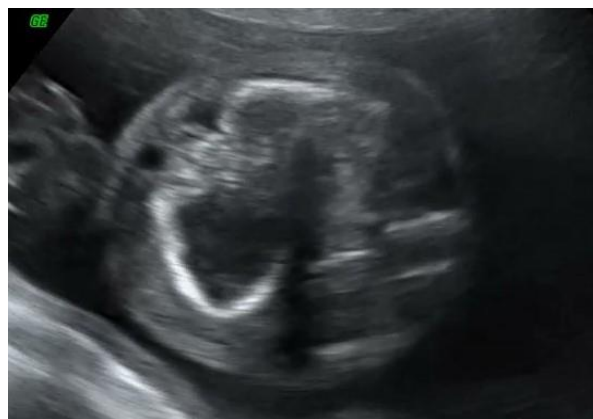## Introduction

Meconium peritonitis is a rare fetal disease due to perforation of bowel in utero and sterile inflammatory reaction related to the extravasation of the meconium. The estimated prevalence is about 1/30,000 live births, and the mortality ranges from 11-50% (1). Ileal atresia, volvulus, Hirschsprung's disease, cystic fibrosis, intussusception, Meckel diverticulitis, colonic atresia, and vascular insufficiency might be the cause of perforation. However, no definitive reason is found in half of the cases (2). It is divided into three categories, namely: fibro adhesive, pseudocystic and generalized types. It depends on when the bowel perforation occurred and the severity of the inflammatory reaction (3). In the prenatal period, it is classified as simple or complex meconium peritonitis according to the severity of the prenatal findings. The prognosis of the cases detected prenatally is better than that of those diagnosed postnatally, even if, in rare cases, the spontaneous resolution might occur without any clinical manifestation. This report shows a rare case of meconium peritonitis with a meconium pseudocyst in a fetus, who was managed conservatively and resolved spontaneously in the postnatal period.

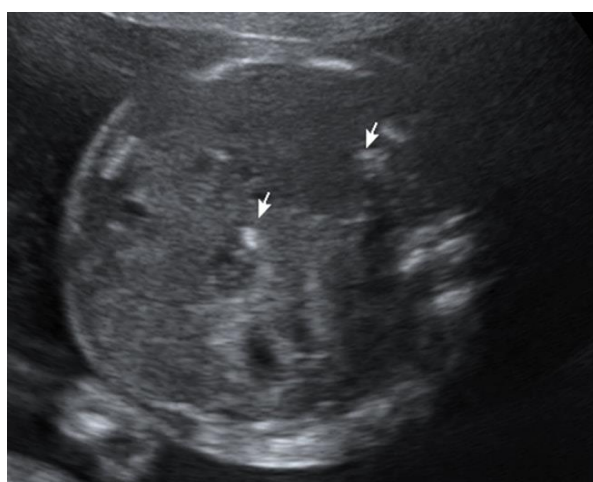## Case Report

A 28-year-old woman gravida two para one was referred to our clinic for intra-abdominal cystic mass and polyhydramnios. There was no known risk factor in the obstetric history, and the first-trimester ultrasound examination was normal. A detailed ultrasound scan at 24 weeks revealed a 52x24x58 mm complex cystic lesion in the fetal abdomen (Figure 1). The cystic mass demonstrates multiple septations and a well-defined hyper-echogenic wall. Color Doppler imaging revealed no abnormal vascularization around the mass. Punctuate calcifications were observed on the surface of the liver and intestine. The amniotic fluid index was increased (AFI: 10 cm) and the fetal biometry was appropriate for the gestational age. The gallbladder was seen in its normal location, and bowel dilatation was not detected. No other abnormalities were noted. Meconium peritonitis was suspected. Fetal MRI was suggested, but the patient did not accept this intervention. Genetic counseling was provided, and amniocentesis was then suggested to determine the fetal karyotype and cystic fibrosis. The patient refused the invasive procedure. Maternal *Toxoplasma gondii* and Cytomegalovirus serology results were normal. The fetal examination was performed twice a month. The cystic mass disappeared after 30 gestational weeks, but punctuate calcifications remained on the surface of the liver and intestinal walls

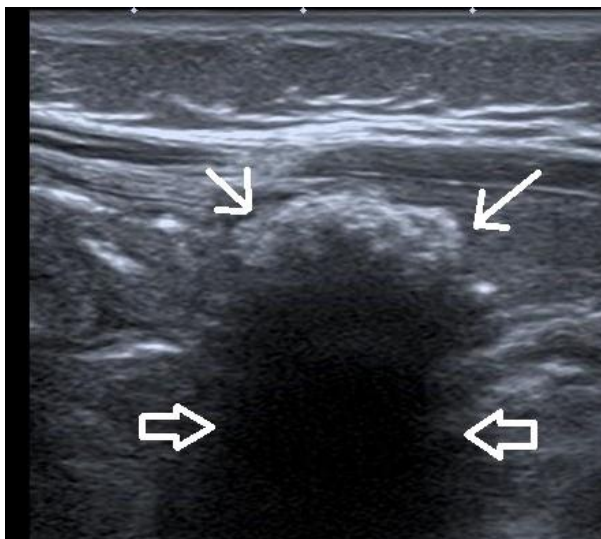
without acid formation (Figure 2). The fetal wellbeing was reassuring during the antenatal period. At 39 weeks of gestation, a 3,670 gr male infant was delivered spontaneously. The postnatal course was uncomplicated and the abdominal examination was normal. The newborn's initial laboratory data revealed mild anemia (Hb 9.7 g/dl). The thrombocyte count, liver enzymes, and coagulation parameters were normal. Breastfeeding was warranted after defecation of the newborn. The ultrasound examination revealed a 20x22 mm hypo-echogenic cystic mass in the right upper abdomen which had acoustic shadowing in the posterior wall due to calcifications (Figure 3). Also, numerous calcification foci existed around Morrison pouch (Figure 4). The diagnosis of meconium peritonitis was confirmed, and clinical observation was considered. Abdominal distension or vomiting were not observed in the postnatal period. A sweat chloride test was performed, and cystic fibrosis was excluded. The neonate was discharged four days after birth. The abdominal cystic mass and calcifications resolved spontaneously at three months of life.



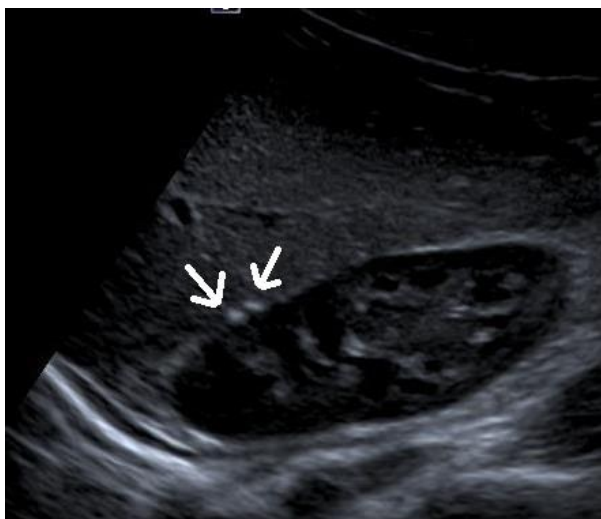
**Figure 1.** An axial ultrasound plan demonstrates complex abdominal mass at 22 gestational weeks



**Figure 2.** An axial ultrasound plan shows multiple abdominal calcifications at 32 gestational weeks



**Figure 3.** Ultrasonographic examination revealed a cystic mass in the right upper abdomen which has acoustic shadowing in the posterior wall due to calcifications at first day of life



**Figure 4.** Ultrasonographic examination showed numerous calcification foci on the liver surface at the first day of life

## Discussions

Meconium peritonitis is a sterile chemical peritonitis caused by bowel perforation with intraperitoneal extravasation of the meconium in utero. Meconium formation begins in the third month of fetal life and includes desquamated squamous cells of the skin, bile acids, uric acid, mucus, intestinal enzyme secretions, etc. After bowel perforation, the digestive enzymes in the meconium induce an exaggerated fibroblastic reaction in the peritoneum. The etiology of bowel perforation may be a decreased blood flow into the mesentery. This condition can cause mucosal hypoxia and hypoperistalsis of bowels and, if persistent, necrosis and perforation might develop

in the intestinal wall. Other causes of perforation are intestinal atresia, intestinal stenosis, volvulus, Meckel's diverticulum, Hirschsprung's disease, Parvovirus B19 or Rubella infections. However, the etiology is unknown in more than half of the cases.

Meconium peritonitis was divided in three pathological variants by Lorimer et al. as follows: the fibro adhesive, the cystic and the generalized type (3). The distinction between them is based on the timing of the fetal onset of perforation and the severity of peritonitis. In the fibro adhesive type, the perforation site is efficiently sealed off by the fibrous bands. It is the most common and the least severe form of the disease. If the perforation site is not entirely closed by the fibro adhesive band, the cystic type can be seen and the meconium continues spilling into the peritoneal cavity. Then, the intestine gets more inflamed and forms a thick wall in the cystic cavity to prevent meconium from spilling into the rest of the bowel. The generalized type is characterized by diffuse bowel thickening, peritoneal fibrosis, and widespread calcifications. It occurs shortly before birth or after that and comprises the most severe forms of meconium peritonitis.

With technical advances and the increasing use of high-resolution ultrasound equipment, much more cases have been diagnosed prenatally in recent years. Intra-abdominal calcifications, ascites, meconium pseudocyst and dilated intestinal loops should be indicative of meconium peritonitis. Polyhydramnios is present in 25-50% of the cases, which is the result of poor intestinal peristalsis. Differential diagnosis includes: intestinal duplication cysts, mesenteric cysts, hydrometrocolpos, neuroblastoma, Wilms' tumor, adrenal hemorrhage and cysts, ovarian cysts and Meckel's diverticulum. A meconium pseudocyst results from a contained bowel perforation consisting in a dilated intestine filled with meconium which has a smooth muscle layer connecting the cyst to the normal intestine, but it has no epithelium because of the inflammation. Polyhydramnios, a complex abdominal mass and prevalent calcifications were consistent with meconium peritonitis in our case. Various classification systems were published in the literature according to prenatal ultrasonographic findings to estimate the prognosis. Kamata et al. divided the disease into three types: massive meconium ascites (type 1), giant pseudocyst (type 2) and calcification and small pseudocyst (type 3) (4). Alternatively, it was classified as simple meconium peritonitis or complex meconium peritonitis by Dirkes et al. Simple meconium peritonitis was identified as the presence of isolated abdominal calcifications, whereas in addition to calcifications, the existence of one or more signs such as

polyhydramnios, bowel dilatation, ascites, and pseudocyst was compatible with complex meconium peritonitis (5). Zangheri et al. reviewed the literature and constituted a scoring system based on the prenatal ultrasound findings. They suggested that the prognosis is good in the presence of isolated abdominal calcifications. However, bowel dilatation, ascites, pseudocyst or polyhydramnios were associated with an increased risk of surgical intervention in the neonatal period (6). Our case was considered as complex meconium peritonitis based on the ultrasound findings.

The role of fetal magnetic resonance imaging (MRI) in the prenatal diagnosis of meconium peritonitis has been recently described. Meconium pseudocyst produces a high-intensity signal in T2-weighted images (7). He et al. demonstrated that fetal MRI could be complementary for defining the features of meconium peritonitis. Moreover, fetal MRI can detect micro colorectum, the indirect sign of ileal atresia which requires postnatal surgery (8).

Cystic fibrosis (CF) is the most common single gene disorder in Caucasians with a ratio of 1 to 2,000-3,000 live births, and it is reported to cause 20-40% cases of meconium peritonitis (9). The sweat chloride test is the primary diagnostic tool in neonates. However, DNA extraction by chorionic villus sampling or amniocentesis and amplification of the CFTR (cystic fibrosis transmembrane conductance regulator) gene through PCR is essential in the prenatal diagnosis. Our patient declined the invasive procedure of CF screening and the sweat chloride test resulted negative after birth.

The clinical signs of intestinal obstruction and abdominal X-ray graphics or ultrasound are crucial for the postnatal diagnosis of meconium peritonitis. The clinical examination of the newborn reveals a distended abdomen, abdominal mass and vomiting frequently accompanied by hypovolemia. The abdominal X-ray detects the peritoneal calcifications. Ultrasonography confirms the presence of the meconium pseudocyst which has clustered calcifications and a curved form. Abdominal calcifications and a small remnant of the meconium pseudocyst can be seen in the ultrasound examination.

Early publishers have reported a high mortality rate in neonatal meconium peritonitis. However, better outcomes have been published in recent years with a survival rate of more than 90% (10). The prognosis of meconium peritonitis is more favorable when detected in utero. The perinatal course depends on the timing of perforation and the severity of prenatal findings. If peritoneal calcifications were the only sign, the postnatal course would usually be

anticipated as excellent. However, bowel dilatation, ascites, pseudocyst or polyhydramnios formation increase the probability of surgical intervention. Prenatal diagnosis affects the prognosis positively in the postnatal period since, close follow-up, planned delivery, appropriate imaging, and timely interventions might be provided. Peritoneal calcifications accompanied meconium pseudocyst and polyhydramnios in our case. In the postnatal period, it was managed conservatively. Probably, it did not require surgery because perforation occurred in the mid-trimester and enough time has elapsed in the uterine life to seal the perforation and to decrease the size of the meconium pseudocyst.

## Conclusions

Clinicians should take into account abdominal calcifications, complex abdominal masses and bowel dilatation in fetal imaging when considering meconium peritonitis. Prenatally diagnosed cases differ from neonatal meconium peritonitis by better prognosis and reduced mortality. Even in complex diseases, the neonatal course might be encouraging and spontaneous recovery might occur.

## Conflict of interest disclosure

There are no known conflicts of interest in the publication of this article. The manuscript was read and approved by all authors.

## Compliance with ethical standards

Any aspect of the work covered in this manuscript has been conducted with the ethical approval of all relevant bodies and that such approvals are acknowledged within the manuscript.

## References

1. Saleh N, Geipel A, Gembruch U, Heep A, Heydweiller A, Bartmann P, Franz AR, Müller A. Prenatal diagnosis and postnatal management of meconium peritonitis. *J Perinat Med.* 2009; 37(5): 535-8. PMID: 19492926, DOI: 10.1515/JPM.2009.097
2. Nam SH, Kim SC, Kim DY, Kim AR, Kim KS, Pi SY, Won HS, Kim IK. Experience with meconium peritonitis. *J Pediatr Surg.* 2007; 42(11): 1822-25. PMID: 18022430, DOI: 10.1016/j.jpedsurg.2007.07.006
3. Lorimer WS, Dick GE. Meconium peritonitis. *Surgery* 1966; 60(2): 470-75. PMID: 5920370

4. Kamata S, Nose K, Ishikawa S. Meconium peritonitis in utero. *Pediatr Surg Int.* 2000; 16(5-6): 377-9. PMID: 10955566
5. Dirkes K, Crombleholme TM, Craigo SD, Latchaw LA, Jacir NN, Harris BH, D'Alton ME. The natural history of meconium peritonitis diagnosed in utero. *J Pediatr Surg.* 1995; 30(7): 979-82. PMID: 7472957
6. Zangheri G, Andreani M, Ciriello E, Urban G, Incerti M, Vergani P. Fetal intraabdominal calcifications from meconium peritonitis: sonographic predictors of postnatal surgery. *Prenat Diagn.* 2007; 27(10): 960-3. PMID: 17654754, DOI: 10.1002/pd.1812
7. Eckoldt F, Heling KS, Woderich R, Kraft S, Bollmann R, Mau H. Meconium peritonitis and pseudocyst preformation: prenatal diagnosis and postnatal course. *Prenat Diagn.* 2003; 23(11): 904-8. PMID: 14634976, DOI: 10.1002/pd.720
8. He F, Yin Y, Huang L, Li H, Cao Y. Using prenatal MRI to define features of meconium peritonitis: an overall outcome. *Clin Radiol.* 2018; 73(2): 135-140. PMID: 28954695, DOI: 10.1016/j.crad.2017.08.006
9. Reynolds E, Douglass B, Bleacher J. Meconium peritonitis. *J Perinatol.* 2000; 20(3): 193-5. PMID: 10802847
10. Ping L.M, Rajadurai VS, Saffari SE. Meconium peritonitis: Correlation of antenatal diagnosis and postnatal outcome-an institutional experience over ten years. *Fetal Diagn Ther.* 2017; 42(1): 57-62. PMID: 27649500, DOI: 10.1159/000449380