

A Case of Horner's Syndrome After the Surgical Treatment of Pulmonary Hydatid Cyst

Pulmoner Kist Hidatik Cerrahisi Sonrasında Gelişen Horner Sendromu Olgusu

Gülsüm İclal BAYHAN¹, Meryem KARACA¹, Ülkü YAZICI², Gönül TANIR¹

¹Department of Pediatric Diseases, Sami Ulus Children's Hospital, Ankara

²Department of Thoracic Surgery, Atatürk Chest Diseases and Thoracic Surgery Training and Research Hospital, Ankara, Turkey

ABSTRACT

We report a case of right-sided iatrogenic Horner's syndrome developed after surgical treatment for pulmonary hydatid cyst. This occurred in a 10 year old girl who had been diagnosed as having a ruptured lung hydatid cyst on the basis of clinical, radiological, serological, histopathological and perioperative findings. The patient underwent right thoracotomy and the cystotomy-capitonnage for the cyst. Right upper lid ptosis, right miosis and anisocoria were recognized on the first postoperative day. Findings of Horner's syndrome were ameliorated completely at the 6th month. In conclusion, iatrogenic transient Horner's syndrome may develop after surgery for pulmonary hydatid cyst, especially if the cyst is located at the lung apex. (*Türkiye Parazitol Derg* 2010; 34: 196-9)

Key Words: Hydatid cyst, Horner's syndrome, child

Received: 10.02.2010

Accepted: 28.09.2010

ÖZET

Bu makalede pulmoner kist hidatik cerrahisi sonrasında gelişen Horner sendromu olgusu sunuldu. 10 yaşında kız hastaya klinik, radyolojik, serolojik, histopatolojik ve perioperatif bulguar ışığında rüptüre pulmoner kist hidatik tanısı kondu. Sağ akciğere torakotomi ile girilerek kistektomi ve kapitonaj ameliyatı yapıldı. Ameliyat sonrasında birinci günde hastanın sağ gözünde pitozis, miyozis ve anizokori saptandı. Horner sendromu bulguları hastanın izleminin altıncı ayında tamamen düzeldi. Sonuç olarak özellikle kist apeksde yerleşmiş ise pulmoner kist hidatik cerrahisi sonrasında iyatrojenik Horner sendromunun gelişebileceğini vurgulamak istedik. (*Türkiye Parazitol Derg* 2010; 34: 196-9)

Anahtar Sözcükler: Kist hidatik, Horner sendromu, çocuk

Geliş Tarihi: 10.02.2010

Kabul Tarihi: 28.09.2010

INTRODUCTION

Horner's syndrome, or oculosympathetic paralysis, was described by Johann Friedrich Horner in 1869. Horner's syndrome occurs following interruption of second order preganglionic neurons, and manifests as miosis, ptosis, hemifacial anhidrosis and enophthalmos (1-3). Horner's syndrome is most commonly detected in adults with apical tumors, although numerous other causes have been described. In children, the causes of Horner's syndrome are

congenital varicella, birth trauma, tumours of the neck and mediastinum such as neuroblastoma, ganglioneuroma and neurilemmoma, and vascular lesions of the internal carotid or subclavian artery. Several case reports describe iatrogenic Horner's syndrome either after a thoracic operation or after placement of a thoracostomy tube for pneumothorax, or as a result of trauma (2, 4, 5).

Echinococcosis is still an important public health problem in endemic areas, including Turkey. Hydatid cyst disease is

Bu makale 53. Milli Pediatri Kongresi'nde Sunulmuştur.

Address for Correspondence/Yazışma Adresi: Dr. Gülsüm İclal Bayhan, Vakıf Gureba Eğitim ve Araştırma Hastanesi, Genel Cerrahi Kliniği, İstanbul, Turkey Phone: +90 312 305 60 00 E-mail: gbayhan@gmail.com

doi:10.5152/tpd.2010.13

caused by the larval form of *Echinococcus granulosus*, and often manifests as a slowly growing cystic mass and mainly affects the liver or lung and, rarely, other parts of the body such as the brain, heart, bone and muscle (6). Lung involvement, which follows hepatic infestation in frequency, has been seen in 30% of the cases of hydatidosis in some series (7). Surgery is considered as a primary method in the management of pulmonary hydatid disease with some risk of complications. It has been reported that surgical treatment in children has a 13.6% morbidity rate with complications such as wound infection and a prolonged air leak (8).

We report a case of iatrogenic Horner's syndrome in a 10-year-old girl who underwent thoracic surgery for a ruptured lung hydatid cyst.

CASE REPORT

A previously healthy 10 years old girl presented to our hospital with chest and shoulder pain of 4 days duration. She also had complaints of cough and expectoration of watery material. Physical examination revealed normal vital signs and decreased breath sounds in the upper region of the right lung. Laboratory examinations were as follows; hemoglobin 12.6 gr/dl, white blood cell count 7.100 (per mm³) (neutrophils 46%, eosinophils 28%, lymphocytes 26%), platelet count 330,000 (per mm³). Serum biochemical investigations were within normal limits. The serum total immunoglobulin E level was 130 IU/ml (normal: <90IU/ml).

A thick-walled cystic lesion containing air-fluid level in the upper region of the right lung was detected on chest x-ray (Figure 1). There was a 107x75mm cavitory lesion including an air/fluid level that ruptured into the bronchial lumen and gross infiltration with partial volume loss in the upper lobe of the posterior segment of the right lobe on the thorax computed tomography (CT). Ground glass opacities surrounded the cystic cavity (Figure 2). A 13x5 mm Grade II hydatid cyst with wall echogenity and lobulated contours located on the right liver lobe was determined on abdominal ultrasonography (US). Anti-echinococcus antibody was positive at a titer of 1/128 with indirect haemagglutination test (IHA). The result of the test was confirmed by the method of Western blotting (WB). Surgical treatment was planned for the ruptured lung hydatid cyst following a thoracic surgery consultation. After a standard posterolateral thoracotomy under general anesthesia, cystotomy was carried out. During the operation, the cyst wall was found to be partially adherent to the pleural surface and chest wall at the apical and posterior regions of the lung. The cyst was completely aspirated and the germinative membrane was removed. After the pleural adhesions had been dissected from the surrounding structures, capitonnage was performed. Histopathological examination of the removed cysts confirmed the diagnosis. The operation was uneventful but right upper lid ptosis, right miosis and anisocoria, which was more obvious in the dark, were recognized on the first postoperative day. Facial anhidrosis was not assessed by lack of sensation on both sides of the face. There were no deficits of ocular motility, enophthalmus or obvious asymmetry of facial sweating. The patient was prediagnosed as iatrogenic Horner syndrome due to thoracic surgery. Magnetic resonance imaging (MRI) investigation of the head and neck were performed to exclude the other causes of Horner syndrome. Both regions were normal.

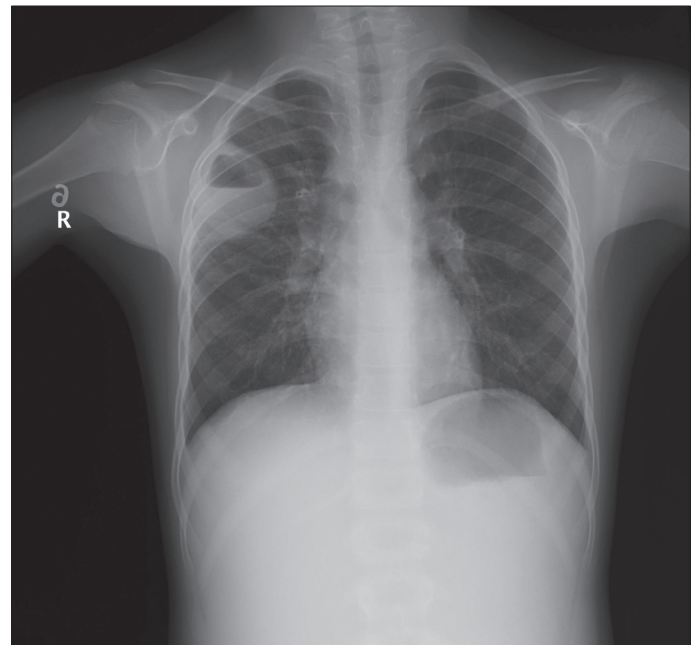


Figure 1. A thick-walled cystic lesion containing air-fluid level in the upper region of the right lung

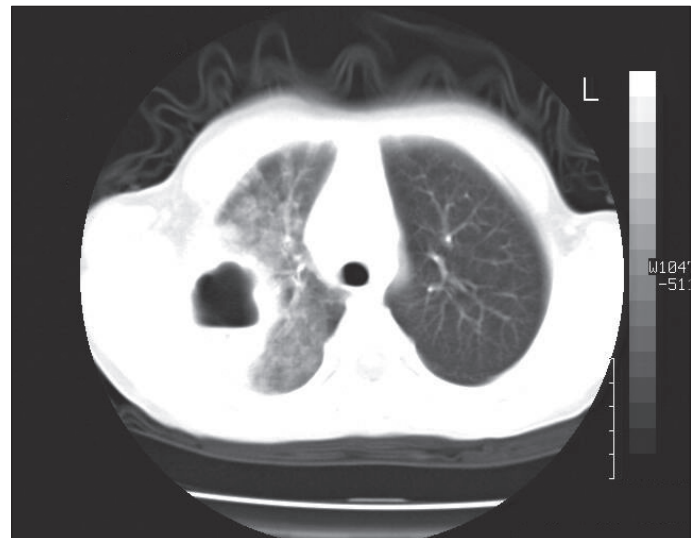


Figure 2. Ground glass opacities surrounded the cystic cavity

Postoperatively, albendazole therapy was given and continued for 6 months with no hepatotoxicity. The chest X-ray was normal postoperatively and serial liver US's revealed diminished diameters of the cystic lesion at follow up visits. She had anisocoria, but her left eyelid ptosis had recovered by 3 months after surgery. Anisocoria of the patient resolved completely at the 6th month control examination.

DISCUSSION

Horner syndrome is a constellation of characteristic symptoms and signs that includes miosis, ptosis, hemifacial anhidrosis and enophthalmos. Horner's syndrome is most commonly caused by local extension of an apical lung tumor at the superior thoracic inlet. Horner's syndrome has been reported also as a complication of some thoracic surgical procedures (5). In our patient,

upper lid ptosis and right miosis were detected but hemifacial anhidrosis and enophthalmos were not observed. The globe was retracted because the sympathetic retractors of the lower lid were relaxed, narrowing the palpebral fissure and giving the observer the illusion of enophthalmos. Because the globe is not truly sunken in cases of Horner's syndrome, enophthalmos is a controversial feature. In a study of 15 patients with Horner's syndrome, upside down ptosis was demonstrated in 10 cases. Miosis occurred in all patients, and ptosis was seen in 14 patients. Enophthalmos was present in only four patients (9, 10). Apraclonidine and cocaine tests are used in the diagnosis of Horner's syndrome (11). However, Horner's syndrome can be diagnosed by clinical findings without the cocaine and apraclonidine tests. Brain, neck, and chest MRI have been recommended in a child of any age with Horner's syndrome without a surgical history to exclude a mass lesion (12). We performed cranial and cervical MRI studies despite the presence of surgical intervention to investigate cranial or cervical cyst hydatid as a cause of Horner's syndrome.

Hydatid cysts can be located in various tissues, the most common presentations are hepatic and lung cysts. In our patient, the hydatid cysts were diagnosed on the basis of clinical, radiological, serological, histopathological and perioperative findings. History of hydatid vomica, a thick-walled cystic lesion containing an air-fluid level detected on the chest X-ray, a cavitary lesion including an air/fluid level and gross infiltration detected on thoracic CT all directed us to the diagnosis of ruptured pulmonary hydatid cyst. A serologically positive IHA result was confirmed by WB. The diagnosis was supported by the macroscopic appearance of the cyst during surgery and determination of germinative membrane on pathologic examination. Serological tests are used to support the clinical diagnosis of hydatid cyst. Among the serologic tests, IgG enzyme linked immunoassay (ELISA) and IHA are two important tests often used in diagnosis and in monitoring the disease in the postoperative period. The usefulness of the commercially available hydatid cyst WB IgG for the serological confirmation of human hydatid cyst was demonstrated (13). The antibody response is lower in lung hydatid cysts compared with liver hydatid cysts; and serologic tests have 80-90% sensitivity in liver hydatid cysts and 50-56% in pulmonary hydatid cysts. The overall sensitivity of the IHA and WB tests in pulmonary hydatid cysts were found as 96.7% and 100%, and the specificities were 82.2% and 85.7% respectively (14-17).

The hydatid cyst of the lung is mainly suggested by imaging techniques, but they must be combined with serological assays. Hydatid cyst demonstrates a variety of imaging features varying according to growth stage, associated complications, and affected tissue (18). Radiological studies are the primary step in the evaluation of pulmonary hydatid cysts. For reasons of cost and availability, the chest X-ray is still the most frequently used examination. In chest radiographs, cysts are well defined as a rounded mass of uniform density. When a cyst is broken, endocyst detachment is seen as floating membranes within the cyst. This 'water-lily' or 'meniscus' sign denoting the entrance of air between the laminated membrane and the pericyst through a bronchiopericystic fistula is observed as a thin, radiolucent crescent in the upper part of the cyst on chest X-ray. Thoracic CT

recognizes certain details of the lesions and their surrounding structures more efficiently and can also uncover additional smaller cysts that were not detected by conventional chest X-ray. The superior imaging definition of CT is particularly useful in the case of complicated cysts, for example, to identify a cyst wall defect in a ruptured cyst (16). Characteristic US findings are anechoic cystic lesions with usually well-defined margins, but they may vary according to the stage of evolution of the disease. There are more than 15 classification schemes for liver hydatid cysts based on their US appearances, and the initial classification by Gharbi et al and the World Health Organization classification are the most commonly used (19). In our patient, a thick-walled cystic lesion containing an air-fluid level was detected on the chest X-ray. In addition to chest X-ray findings, rupture of the cyst was found on thoracic CT examination as ground glass opacities that surrounded the cystic cavity. Our patient also had a Grade II hydatid cyst with wall echogenicity and lobulated contours on the right liver lobe. Fluid collection with a split wall has been shown in Grade II hydatid cysts (19).

The treatment of pulmonary hydatid cysts is commonly surgical. The choice of approach mainly depends on the location of the cyst. Generally, parenchyma-preserving conservative methods (cystotomy and capitonnage, enucleation, and pericystectomy) are the preferred procedures. Segmentectomy, lobectomy, and pneumonectomy could be required if there are multiple unilocular cysts or a giant cyst (a cyst involving more than 50% of the lobe), or severe pulmonary suppuration not responding to treatment. A total cyst excision is performed for patients with extrapulmonary/intrathoracic hydatid disease. Our patient had a pulmonary hydatid cyst less than 5 cm in size, but it had ruptured into the bronchial lumen on presentation. History of hydatid vomica, the CT finding of ground glass opacities surrounding the cystic cavity that was evaluated as a parenchymatous reaction to bronchial rupture and peripheral blood eosinophilia were findings of ruptured hydatid cyst in our patient (7, 15, 20). The postoperative complication rate of hydatid disease ranges between 1% and 19%. Wound infection and a prolonged air leak are reported as the most common postoperative complications. The postoperative mortality and morbidity rates were higher in complicated pulmonary hydatid cysts than intact cysts (21). Horner's syndrome due to thoracotomy was reported only few cases. Horner's syndrome occurs from the interruption of the sympathetic chain along its course from the hypothalamus to the eye. Thoracic sympathetic chains (stellate ganglion) are often surrounded by small pads of fat-laden tissue at the apex of the hemithorax. Injury to the stellate ganglion may result in 2-5% temporary and 1-2% permanent ipsilateral Horner's syndrome. In a prospective clinical study Horner's syndrome was detected in twelve patients out of 933 adult patients (1.3%) who underwent thoracic surgery or who had thoracic trauma (5). Apical electrocautery burn in related thoracotomy and lung resection was found to be the cause of Horner's syndrome (5) Horner's syndrome could possibly be the result of thermal injury of the stellate ganglion during the cystotomy and capitonnage operation of the cyst located on the right upper lobe in the present case. Horner's syndrome associated with pulmonary, especially mediastinal, hydatid cyst disease has rarely been reported (22).

However, Horner's syndrome is an unusual complication of hydatid cyst surgery, and, to our knowledge, there have been no previously reported cases.

Mebendazole and albendazole are used as primary therapy, or as an adjunct therapy to surgical and percutaneous procedures. Preoperative medical treatment is not used currently, since it may cause rupture of the cyst. Postoperative medication is usually recommended in recurrent cases and in cases with multiple cysts. The recurrence rate is as high as 11% in the absence of postoperative antihelminthic therapy (23). Albendazole was used as a postoperative measure in our patient with success.

In Horner's syndrome, spontaneous resolution of the ptosis follows sympathetic regeneration with reestablishment of the original sympathetic pathways. If spontaneous recovery of the ptosis is not evident within 6 months, this is readily treated by a levator palpebrae tuck or section (24). We observed improvement of ptosis, myosis and anisocoria in six months. We concluded that Horner's syndrome may develop after surgery for pulmonary hydatid cyst, especially if the cyst is located at the apex, and may resolve spontaneously.

Conflict of Interest

No conflict of interest was declared by the authors.

REFERENCES

1. Blanco CI, Buznego L, Méndez M. Horner's syndrome after tonsillectomy. *Arch Soc Esp Oftalmol*, 2008; 83: 129-31
2. Jeffery AR, Ellis FJ, Repka MX, Buncic JR. Pediatric Horner syndrome. *J AAPOS*, 1998; 2: 159-67.
3. Ozel SK, Kazez A. Horner syndrome due to first rib fracture after major thoracic trauma. *J Pediatr Surg*, 2005; 40: 17-9.
4. George ND, Gonzalez G, Hoyt CS. Does Horner's syndrome in infancy require investigation? *Br J Ophthalmol*, 1998; 82: 51-4.
5. Kaya SO, Liman ST, Bir LS, Yuncu G, Erbay HR, Unsal S. Horner's syndrome as a complication in thoracic surgical practice. *Eur J Cardiothorac Surg*, 2003; 24: 1025-8.
6. *Pediatr Surg Int*, 2002; 18: 417-9.
7. Ramos G, Orduña A, García-Yuste M. Hydatid cyst of the lung: diagnosis and treatment. *World J Surg*, 2001; 25: 46-57.
8. Dincer SI, Demir A, Sayar A, Gunluoglu MZ, Kara HV, Gurses A. Surgical treatment of pulmonary hydatid disease: a comparison of children and adults. *J Pediatr Surg*, 2006; 41: 1230-6.
9. Nielsen PJ. Upside down ptosis in patients with Horner's syndrome. *Acta Ophthalmol*, 1983; 61: 952-7.
10. Van der Wiel HL, Van Gijn J. Horner's syndrome: Criteria for oculosympathetic denervation. *J Neurol Sci*, 1992; 56: 293-8.
11. Van der Wiel HL, Van Gijn J. The diagnosis of Horner's syndrome. Use and limitations of the cocaine test. *J Neurol Sci*, 1986; 73: 311-6.
12. Walton KA, Buono LM. Horner syndrome. *Curr Opin Ophthalmol*, 2003; 14: 357-63.
13. Liance M, Janin V, Bresson-Hadni S, Vuitton DA, Houin R, Piarroux R. Immunodiagnosis of Echinococcus infections: confirmatory testing and species differentiation by a new commercial Western Blot. *J Clin Microbiol*, 38:3718-21. Mirzai H, Baser EF, 2006. Congenital Horner's syndrome and the usefulness of the apraclonidine test in its diagnosis. *Indian J Ophthalmol*, 2000; 54: 197-9.
14. Ozel SK, Kazez A. Horner syndrome due to first rib fracture after major thoracic trauma. *J Pediatr Surg*, 2005; 40: 17-9.
15. Eris FN, Akisu C, Aksoy U. Evaluation of Two ELISA and Two Indirect Hemagglutination Tests for Serodiagnosis of Pulmonary Hydatid Diseases. *Korean J Parasitol*, 2009; 47: 427-9.
16. Santivanez S, Garcia HH. Pulmonary cystic echinococcosis. *Current Opinion in Pulmonary Medicine*, 2010; 16:257-61
17. Sbihi Y, Rmiqui A, Rodriguez-Cabezas MN, Orduña A, Rodriguez-Torres A, Osuna A. Comparative Sensitivity of Six Serological Tests and Diagnostic Value of ELISA Using Purified Antigen in Hydatidosis *Journal of Clinical Laboratory Analysis* 2001; 15: 14-8.
18. Ozyurtkan MO, Balci AE. Surgical treatment of intrathoracic hydatid disease: a 5-year experience in an endemic region. *Surg Today*, 2010; 40: 31-7.
19. Turgut AT, Akhan O, Bhatt S, Dogra VS. Sonographic Spectrum of Hydatid Disease. *Ultrasound Quarterly*, 2008; 24: 17-29
20. Long SS, Pickering LP, Prober CG. Laboratory manifestations of infectious diseases. Long SS, Nyquist A-N. Principles and Practice of Pediatric Infectious Diseases. Pennsylvania: Churchill Livingstone Inc. p. 2003; 1409-22.
21. Nielsen PJ. Upside down ptosis in patients with Horner's syndrome. *Acta Ophthalmol*, 1983; 61: 952-7.
22. Ozpolat B, Ozeren M, Soyal T, Yucel E. Unusually located intrathoracic extrapulmonary mediastinal hydatid cyst manifesting as Pancoast syndrome. *J Thorac Cardiovasc Surg*, 2005; 129: 688-9.
23. Botrugno I, Gruttadauria S, Li Petri S, Cintorino D, Spada M, Di Francesco F, Pagano D, Crino F, Anastasi D, Gridelli B. Complex hydatid cysts of the liver: a single center's evolving approach to surgical treatment. *Am Surg*, 2010; 76: 1011-5.
24. Singh B, Moodley J, Allopi L, Cassimjee HM. Horner syndrome after sympathectomy in the thoracoscopic era. *Surg Laparosc Endosc Percutan Tech*. 2006; 16: 222-5.