

# **LIONFISH INVASION AND ITS MANAGEMENT IN THE MEDITERRANEAN SEA**

**Edited by**  
M. Fatih HÜSEYİNOĞLU and Bayram ÖZTÜRK

# LIONFISH INVASION AND ITS MANAGEMENT IN THE MEDITERRANEAN SEA

All rights are reserved. No part of the publication may be reproduced, stored in a retrieval system, or transmitted in any form or by any means without the prior permission from the Turkish Marine Research Foundation (TUDAV).

© Turkish Marine Research Foundation  
ISBN: 978-975-8825-41-7

Citation: Hüseyinođlu, M.F., Öztürk, B. (Eds.) 2018. Lionfish Invasion and Its Management in the Mediterranean Sea. Turkish Marine Research Foundation (TUDAV) Publication number: 49, Istanbul, Turkey, 121 pages.

Cover photo: *Pterois miles* © Bayram Öztürk (TUDAV)

Available from: Turkish Marine Research Foundation (TUDAV)  
P.O. Box: 10, Beykoz, Istanbul, Turkey  
Tel: 0(216) 424 07 72  
Fax: 0(216) 424 07 71  
E-mail: tudav@tudav.org  
www.tudav.org

Printed: MetinCopyPlus / Artı Dijital & Baskı Merkezi  
Türkocađı Cad. 3/A Türkiye Gazeteciler Cemiyeti Altı  
İran Konsolosluđu Karşısı Cađalođu/Fatih/İstanbul  
Tel: 0212 527 61 81  
E-mail: info@metincopyplus.com  
www.metincopyplus.com

## **Lionfish envenomation: epidemiology, management and prevention**

**Selin Gamze SÜMEN<sup>1\*</sup>, Bengüsu MİRASOĞLU<sup>2</sup>, Şamil AKTAŞ<sup>2</sup>**

<sup>1</sup> Health Science University, Kartal Dr Lutfi Kırdar Research and Training Hospital, Department of Underwater and Hyperbaric Medicine, TURKEY

<sup>2</sup> Istanbul University, Istanbul Faculty of Medicine, Department of Underwater and Hyperbaric Medicine, TURKEY

\*Corresponding author: sgsumen@gmail.com

---

*We are all impressed by the beauty of its colors and feathery rays when we come across with her in the deep blue ocean. She looks like she popped out of a fashion show. She quickly recognises us and keeps on staring to all divers surrounding her. She turns round and round smoothly trying to discover the possible threats. If we attempt to approach her, she looks more impressive than any other creature by opening her thorns like a feathery fan. Her message is clear: "If you threaten me I can be painful, please do not disturb me".*

### **Introduction**

A sea creature is labelled as venomous, if it has a special tool for injecting venom. Toxic secretions discharged through special body parts such as teeth, stings, nematocysts, or hairs which are essential to defend or catch prey for some animals. Fish spines and venom apparatus are usually protection shields for sea animals in case of threats emerging from their predators (Jung and Bodio 2006). By fancy and colorful spines, fish attract and hunt other surrounding creatures like small fish and use their venomous spines to incapacitate their prey for feeding. However sometimes humans can be targeted. Fish envenomation may cause severe clinical symptoms and result in the fatality of victims shortly after the injury. The severity of the injury depends on the intensity of the envenomation and the predispositional factors of individual such as allergy, age, immune compromised conditions and other comorbidities.

The lionfish (*Pterois volitans* and *Pterois miles*) is a venomous fish from the Scorpaenidae family, which consists of stonefish (synanceia), scorpionfish (scorpaena) and lionfish (pteroinae) in order of venom potency (Diaz 2015; Garyfallou 1996). Although there are records of a few subspecies in Polar Regions, lionfish species mostly prefer tropical, subtropical and temperate regions. Common lionfish is native to Indian Ocean and Red Sea but also inhabit Indo-Pacific, Atlantic, and Australian waters. It has entered the Mediterranean Sea as a Lessepsian species. It is also hypothesized that it was transported via ballast tanks of large vessels from native marine environment through Suez Canal and reproduced rapidly (Maclsaac 2016; Bariche *et al.* 2017; Zenetos *et al.* 2012;

Por 1971). Other theories regarding spreading of lionfish are release from aquariums or results of global warming. Also, devastating effects of Hurricane Andrew in United States are thought to be important around Atlantic area. Six lionfish were freed when Hurricane Andrew destroyed a large marine aquarium at the edge of bay. These lionfish were seen alive in the sea several days later (Schmitt and de Haro 2013; Courtenay 1995; Diaz 2015; Ruiz-Carus *et al.* 2006). Regardless of the way they were introduced to non-native waters, this invasive fish species has become a major predator for other native species and threat to major habitats.

First encounter in Mediterranean Sea was at Haifa Bay in 1991 (Golani and Sonin 1992). In 2014, Turan and *et al.*, reported the first lionfish (identified as *Pterois volitans* but not confirmed) in Turkey at the southeast part of coastal region of Mediterranean Sea (Turan, *et al.* 2014). A year later, another lionfish (*Pterois miles*) occurrence at 11 m depth on sandy bottom was reported in Southwestern coasts of Turkey on the Sea (Turan and Öztürk 2015). These records are proofs that lionfish are spreading rapidly and we will encounter lionfish more around our coasts in the near future.

Lionfish sting is extremely painful and systemic symptoms including syncope, agitation, palpitation, muscle weakness may occur. Fortunately, life threatening manifestations are rarely seen (Diaz 2015). However case reports indicate lionfish envenomations are increasing nowadays (Resiere *et al.* 2016; Diaz 2015). Therefore, it should be a priority to create awareness and prepare strategies related to prompt diagnosis, initial treatment and prevention of the injury. The objective of this chapter is to provide detailed information about lionfish envenomation.

## **Epidemiology**

Lionfish population has gradually increased, resulting in emerging new envenomation cases. Lionfish envenomations do not pose a significant problem in their native habitat but they are a potential threat for local fishermen, divers, aquarists and swimmers who intendedly or unintendedly hold the fish. There is no accurate (or estimated) data regarding its prevalence in the World. There are a little more than 360 reported cases of lionfish envenomations which commonly involve swimmers, divers, fishermen, and aquarists. (Forrester 2008; Alfredi *et al.* 1996; Vetrano *et al.* 2002; Haddad *et al.* 2015; Schult *et al.* 2017). Most accidents take place in the warmer months of the year.

## **Pathophysiology**

Lionfish has 12-13 dorsal, 2 pelvic and 3 anal spines each of which is covered with loose integument that contains two grooves on the sides of the spines. Each groove is connected to a venom gland at the base of spine. The gland is a colorless tissue and can secrete about 3 to 10 mg of venom per thorn. The main mechanism of intoxication emerges if the victim handles, touches or steps on the fish. When the spine penetrates the skin and soft tissue, loose sheath is pushed down and a

pressure is applied on the gland. This causes the venom to discharge from the glands (Auerbach 1991; de Haro and Pommier 2003). The venom is delivered through the bilateral grooves to the puncture area (Vetrano *et al.* 2002).

The venom is composed of high molecular weight proteins that have acetylcholine and antigenic character. These proteins are heat-labile and lose their structure at 50-60 °C. Due to high molecular weight antigenic protein property of the toxin, systemic reactions emerge (Cohen and Oleg 1989; Kizer *et al.* 1985). Toxins in the venom trigger pain through bradykinin receptors. They cause weakness and transient muscle paralysis by disturbing neuromuscular conduction; muscle contractions, cell necrosis, and serum CPK (Creatine Phosphokinase) and AST (Aspartate Aminotransferase) elevations by the increase of intracellular calcium levels (Church *et al.* 2003). Also, toxins are shown to cause alterations in heart rate (tachy and bradycardia) and blood pressure (hypo and hypertension) through adrenergic and muscarinic receptors. Besides these, it's thought that they have cytotoxic, proinflammatory and prothrombotic effects (Cohen and Oleg 1989; Church *et al.* 2003; Church and Hodgson 2002). Acetylcholine is thought to be responsible for muscle fibrillation (Cohen and Oleg 1989). It should be noted that the venom can retain full potency up to 48 hours even after animal's death (Resiere *et al.* 2016).

### **Clinical manifestation**

Symptoms and findings are divided into two groups; local and systemic clinical characteristics (see Table 1). It is not possible to predict how the symptoms will start and what the prognosis will be. Mostly, severe local pain at the puncture area is the first symptom. Other symptoms develop in time, depending on the amount of venom injected and individual factors. Distribution of clinical presentations and complications are summarized in Table 2 (Resiere *et al.* 2016).

Local features: After the injury, the first symptom is usually intense local pain which extends proximally. Pain increases in intensity over the next few hours and may continue about 6-12 hours. The victims describe the pain as unbearable and like heating the flesh with a hot iron bar. It usually relieves after a few hours, but rarely may persist for weeks (Haddad *et al.* 2015; Resiere *et al.* 2016). While the punctured wound is numb, there is increased sensitivity at the surrounding tissue. Weakness, paralysis and muscle contraction can occur at the injured extremity. Pain and tenderness may occur in regional lymph nodes, even disseminating to the central part of the body. Puncture wound may be seen on the affected limb. Puncture wounds are holes caused by long objects such as needles and spines. They do not bleed profusely but may carry dirt and foreign material into the body tissues which may cause infection. Puncture site may be encircled by inflammatory edema and sometimes bluish cyanotic zone around. The surrounding tissues become pale and cyanotic with blistering edema. Rarely tissue necrosis is seen. Wounds from the sting of lionfish are graded based on the

severity: Grade 1) erythema, cyanosis, pallor, ecchymosis at the puncture site. These result from increased capillary permeability; Grade 2) vesicle or bullous lesion formation; Grade 3) local necrosis of the site (Fernandez *et al.* 2011).

**Table 1.** Local and Systemic Findings, Management of Lionfish envenomation

<b>Local Signs and Symptoms</b>	<b>Systemic Signs and Symptoms</b>	<b>Treatment Management</b>
Intense pain Erythematous rash Local edema Numbness Bleeding	Weakness Syncope Dyspnea Hypotension Hallucination Soft tissue infection	1. Removal of all spines and foreign materials preferably with gloved hands and forceps 2. Cleaning with clear water 3. Direct pressure to prevent bleeding 4. Immersion of wound site in hot water (42-45°C) for 30-90 min to relieve acute pain. It can be repeated. 5. Use of oral or parenteral analgesics in case of persistent pain 6. Tetanus prophylaxis 7. Observation of patient for 6–12 h. 8. Prophylaxis with antibiotics if there is a risk of soft tissue infection and contaminated seawater. 9. Surgical debridement if there are signs of necrosis at the wound
	Respiratory arrest Cardiorespiratory collapse Shock	1. Urgent intubation and mechanical ventilation 2. Supportive care 3. Critical care management

**Table 2.** Distribution of clinical presentations and complications of the patients

<b>Signs and Symptoms</b>	<b>% of cases</b>	<b>Clinical Complications</b>	<b>% of cases</b>
Pain and local edema	100	Local infection	18
Paraesthesia	90	Skin abscess	5
Abdominal cramps	62	Cellulitis	3
Extensive edema	53	Skin necrosis	3
Tachycardia	34	Septic arthritis	2
Skin rash	32	Hospitalization	22
Gastrointestinal disorders	28	Requiring surgery	8
Fainting	27		
Transient weakness	24		
Hypertension	21		
Hypotension	18		
Hypophosphatemia	12		
Elevated liver enzyme aspartate aminotransferase (AST)	10		
Hyperthermia	9		
Bradycardia	3		
Thrombocytopenia	3		

Puncture wounds can get infected. Local infections may advance rapidly to soft tissue infection such as cellulitis, myositis and necrotizing fasciitis and result with severe sepsis. The infection agents can be marine related bacteria like *Vibrio* and *Aeromonas* species which can cause systemic infection and death. It should be noted that risk of serious necrotizing infections are much higher for immunocompromised people (Diaz 2014). Also unspotted spines that remained embedded in the tissue may cause pain, edema, itching and even loss of mobility if located near joints (Diaz and Lopez 2015).

**Systemic features:** Systemic symptoms are not very common but if present they may vary from mild to severe. The victim may suffer anxiety that may result with hallucinating state due to the intensity of the pain. Mostly, nervous system, cardiovascular system, digestive system and skin are affected. Malaise, nausea, vomiting, and sweating associated with mild fever may be present. Pallor, sweating, hypotension, bradycardia and syncope may occur. Respiratory distress, cardiac dysrhythmias, and cardiac arrest may also develop in severe cases. Cardiovascular shock and death are very rare but possible (Haddad *et al.* 2015; Resiere *et al.* 2016). Hypersensitivity to the venom may develop and anaphylactic reactions can be seen in subsequent envenomations. Hypersensitivity is a strong systemic reaction to a foreign matter entering the body. The extreme response is anaphylaxis, which may result in anaphylactic shock, if untreated, the victim can die. Fish sting may cause severe anaphylaxis, which is a constriction of the air passages and prevents the intake of oxygen at all. It is not clear what triggers

the attack but it happens very quickly, within seconds. Signs and symptoms of this extreme allergic reaction include difficulty breathing, pale skin, cyanosis (blue lips or fingernails), sweating, rapid pulse, syncope and cardiac arrest.

The recovery period may vary from several hours to a few days and symptoms regarding can prolong. Generally symptoms regress in a few days but rarely malaise and nausea may persist (Zelaya 2012; Aktaş and Mirasoğlu 2017).

### **Medical management**

Lionfish envenomation requires immediate action. Medical help should be started as soon as the injury is identified. In case of life threatening conditions, appropriate life-saving procedures should be promptly initiated in the prehospital care settings and victims later should be evaluated at the hospital for possible anaphylactic reactions and other serious conditions of the envenomation. In general, medical management can be considered in two steps, pre hospital and hospital care.

### **Prehospital care**

The injured person should be removed from the sea and transported to a dry and safe place if the incident takes place in water. The victim preferably should be kept in lying down and reassured. If possible, injured part should be raised as this can help to reduce swelling. The wound should be cleaned with warm saline or antiseptic solutions. Early rinsing of the injured area with warm water will help to flush away the foreign bodies and reduce pain intensity. Bleeding, if present, should be stopped with slight pressure. Visible spines and all other foreign bodies should be removed cautiously. Although it is rare for spines to break in the wound, protective gloves should be worn to avoid self-inoculation during spine removal. Tweezers are handy for removing spines from the wound, but this should be done with caution as intact venom glands may discharge if pressure applied. Rings, watches, bracelet and other potential constricting items should be removed carefully before edema sets in (Resiere *et al.* 2016; Atkinson *et al.* 2006; Vetrano *et al.* 2002).

Pain control is the mainstay of the management. Foremost important method for pain relief is warm water immersion (Hornbeak and Auerbach 2017). Underlying mechanism of this treatment is unknown. The claim that heat-labile components of the venom would be deactivated (and so the venom) in hot water is questionable (Atkinson *et al.* 2006). Proteins denature over 50-60 °C but humans cannot tolerate water at those temperatures. In addition, it should be kept in mind that burns or scalding may occur with water at 40-45°C. Deterioration of pain when hot water immersion is suspended is a proof that proteins are not deactivated (Haddad *et al.* 2015). It is thought that heat application provides vasodilatation that reverses the vasoconstriction caused by the venom and pain ceases.



There are a few reports stating that hot application may fail to cease intense pain. Hot water immersion can be applied for 30-90 minutes and repeat several times until the pain decreases. If the location of wound is difficult for immersion, both showering and hot compress can also be preferred (Atkinson *et al.* 2006). Allergic and anaphylactic reactions should always be taken into account and medication with antihistamine, corticosteroid, adrenaline should be implemented rapidly if necessary. Care providers should be prepared for possible cardio pulmonary resuscitation.

### **Hospital care**

Once the patient is stabilized, transportation to a well-equipped hospital where further therapy is planned should be provided. Patients with lionfish envenomation should be hospitalized due to the possibility of delayed allergic or systemic reactions. If systemic manifestations develop, adequate treatment should be planned. There is lack of scientific research regarding lionfish envenomation. It is widely accepted that symptoms and treatments may vary between individuals. However, there are certain treatment algorithms that should be followed. Descriptive analysis of case series is shown in Table 3.

The basic vital signs (temperature, pulse, blood pressure, respiration rate and rhythm, central venous pressure, pulse oximeter) should be monitored and recorded in case of deterioration. Recording of the clinical state is mandatory to monitor the treatment procedure. These records should include pulse, respiratory rate and rhythm, blood pressure, electrocardiogram, lung function test, urine output, arterial gases and acid-base balance of the blood (Edmonds 2002; Diaz 2015).

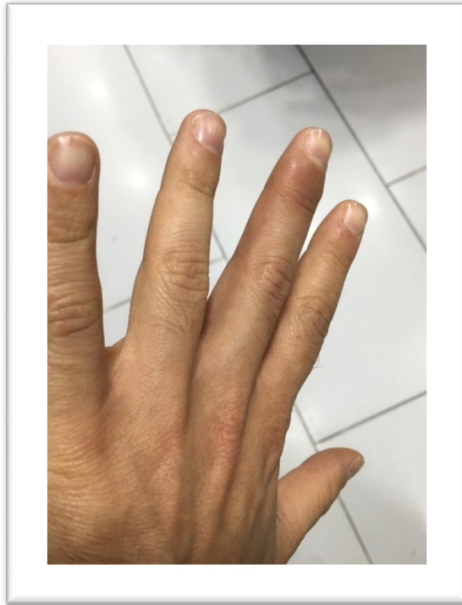
Radiological examinations like soft-tissue X-ray, ultrasound as well as magnetic resonance can be used to disclose bone injury, retained foreign objects or integument of the spine. For serious and extensive lesions, radiological evaluation may help to assess significant tissue damage and necrosis in the wound. In this case, surgical debridement should be performed immediately (Edmonds 2002). If spines or foreign materials are embedded in tissue, surgical removal is a must (Hornbeak and Auerbach 2017). Puncture wound is seen with local edema, mild ecchymosis at the lateral site of the middle finger by sting of lionfish in Figure 1. Moreover, the radiological imaging of the left hand of the patient shows the spine of fish which was embedded in the soft tissue close to the distal interphalangeal joint in Figure 2.

**Table 3.** Descriptive analysis of case series of lionfish envenomation

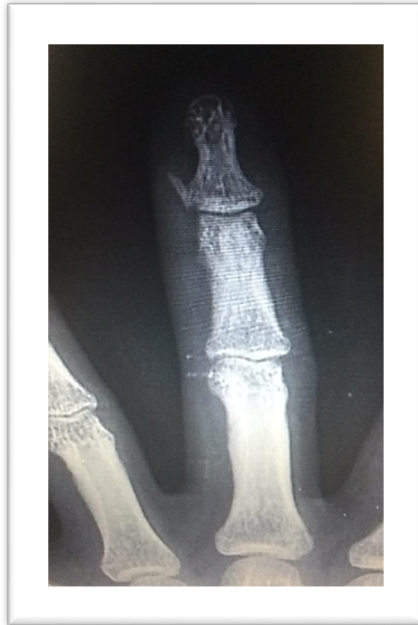Reference Year	Number of cases	Origin	Envenomation sites	Major symptoms	Systemic signs & findings	Treatments	Clinical outcome
Trestrail <i>et al.</i> 1989	23	Aquarium	Hand finger	Pain Redness Swelling Bleeding	Nausea Numbness Joint pain Anxiety Headache Disorientation Dizziness	Hot water immersion Analgesics Antibiotics Tetanus vaccination	Improvement
Alfredi <i>et al.</i> 1996	33	Aquarium	Hand	Pain Redness Swelling	Speech (disarthria) Jaw tightness impairment	Hot water immersion Supportive treatment Tetanus vaccination Topical antibiotics Analgesics Bleed out poison Ice water	Improvement
Vetrano <i>et al.</i> 2002	1	Aquarium	Hand	Pain Edema Bullous lesion	Nausea Dizziness Paresthasias	Hot water immersion Analgesic	Improvement
Badillo <i>et al.</i> 2011	1	Aquarium	Hand	Pain	Paralysis of all extremities Hypertension Tachycardia Numbness of both hands	Hot water immersion Supportive treatment	Improvement

**Table 3.** Continued

Haddad <i>et al.</i> 2015	15	Aquarium	Hand, finger	Pain Erythema Edema	Behavioral changes Sweating Restlessness Nausea Vomiting Diaphoresis Urticaria	Hot water immersion Analgesics Antibiotics	Improvement
Schult <i>et al.</i> 2017	1	Aquarium	Forearm	Pain Erythema Bleeding Edema Puncture wound		Hot water immersion Analgesics Tetanus vaccination	Improvement
Resiere <i>et al.</i> 2016	117	No information	Upper or lower limb	Pain Redness Swelling	Paresthesia Abdominal cramps Extensive edema Tachycardia Skin rash Gastrointestinal symptoms Fainting Transient weakness Hyper/hypotension Hyperthermia Bradycardia Hypophosphatemia	Hot water immersion Analgesic Antibiotics Tetanus vaccination	Improvement



**Figure 1.** Sting site by lionfish, a month after envenomation. Puncture wound is seen with local edema, mild echymosis at the lateral site of the middle finger.



**Figure 2.** Radiologic imaging of the left hand of the patient. The spine of fish was embedded in the soft tissue close to the distal interphalangeal joint.

Systemic antibiotics may be recommended if secondary soft tissue infections develop. Antibiotherapy should be planned according to culture-sensitivity tests when there is a wound to collect a culture specimen. In this case, microbiology laboratories should be informed in advance about the possible agents since special procedures are necessary for marine based microorganisms. If empirical therapy is to be given, distinctive properties of these microbes should be considered. Prophylactic use is not recommended unless the injured person has immunodeficiency disorder (Diaz 2014; Diaz and Lopez 2015).

Systemic analgesics and narcotics are rarely indicated as hot water immersion may help to provide pain relief. *Clostridium tetani* can exist in coastal shorelines and tidal waters although it is known to be soil based. Therefore, tetanus prophylaxis is recommended for all patients who have encountered traumatic marine injury and is unsure about previous immunization (Diaz 2014; Diaz and Lopez 2015).

Although very rare, health care providers should be prepared for resuscitation (including endotracheal intubation, external cardiac massage, and defibrillation) as allergic reactions, convulsions, cardiovascular shock and as well as respiratory arrest requiring assisted ventilation may develop.

There is no specific antivenom for lionfish envenomation. Stonefish antivenom has been shown to cross-react with lionfish venom but it is rarely indicated since lionfish envenomation is milder and usually responds to conventional treatments. Antivenom is rarely indicated for lionfish unless symptoms are persistent and unresponsive to hot water immersion as well as adjunctive treatments (Diaz 2015).

Divers also can be injured by lionfish during the dive and it may not easy to deal with the accident. Although basic management is the same, some specific actions may be necessary for underwater accidents. Some recommendations for divers are listed.

1. Remaining calm is important. Alert your dive partner and terminate your dive as soon as possible.
2. Ascend slowly, complying with all decompression stops, and come to the surface immediately.
3. Monitor vital signs such as circulation, airway and breathing.
4. Rinse the wound with clean water or warm saline solution.
5. Immerse the wound in heated, non-scalding water (42-45 °C) from 30 to 90 minutes. Please remember that warm application is effective for only pain relief.
6. Go to a health care center if there is one in close proximity or call emergency hotline 112 (in Turkey) as soon as possible and ask for help from a marine injury specialist who will coordinate the medical procedures necessary for a lionfish envenomation.

7. If you are far from a medical center, you could take medication such as antihistaminic and analgesic during transportation to the health care center. This immediate care can reduce the damage to the affected part of the body.

8. You can get additional information and help by calling emergency hotlines in other countries. Once the victim has received the first aid and emergency treatment please contact Turkish Marine Research Foundation (TUDAV) (E-mail: tudav@tudav.org, Phone: +90 216 424 07 72) for the record.

## **Prevention**

The best prevention is not to touch a lionfish even with gloves. It is clearly stated that neoprene gloves, booties and soles are not fully protective in case of touching the fish (Aktaş and Mirasoğlu 2017). Thick-soled shoes should be worn when entering or leaving in potential areas, and extreme care must be taken when swimming on coral reefs.

When considered generally, the main step in prevention is creating awareness and training. People who can encounter the fish and are at risk (like local fishermen) should be informed about the physical appearance of lionfish, how to handle one, and the fact that fish remains to be venomous for about 48 hours after its death (Resiere *et al.* 2016). Therefore, holding the fish with bare hands should be avoided and spines should be cut in the proper way immediately after fishing. In the long term, lionfish population control gains importance. Awareness should be raised about over population and solutions should be developed to make lionfish economically significant. Use of venom in medicine can be provided by pharmaceutical industry.

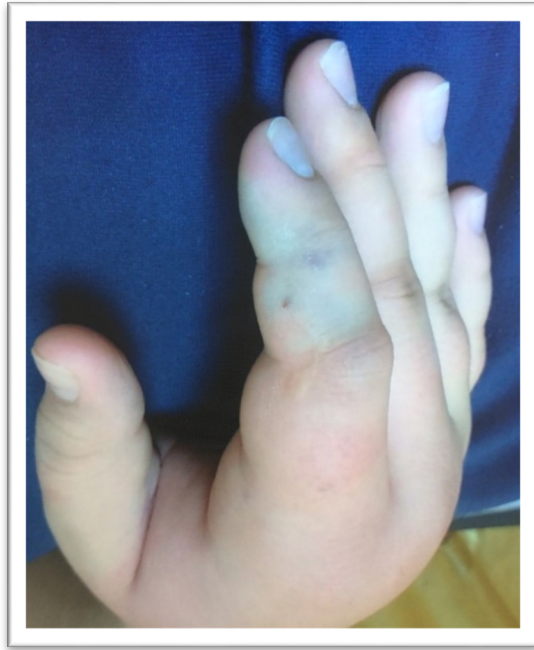Conclusively, envenomation by lionfish as well as scorpionfish and other exotic animals, can rapidly lead to incapacitating and life-threatening complications so health care providers should be trained to manage these injuries. Due to the limited available information regarding envenomation by sea animals, the scientific institutions should share their experience and prepare action plans to record and track these injuries in a yearly period. Involved partners should develop and implement warning mechanisms by means of coordination of scientific research and fruitful collaboration. Nevertheless, since these are infrequent intoxications, the physicians are strongly recommended to consult with the National Poison Control Center by calling 114 and Turkish Marine Research Foundation (TUDAV).

## Recommendations

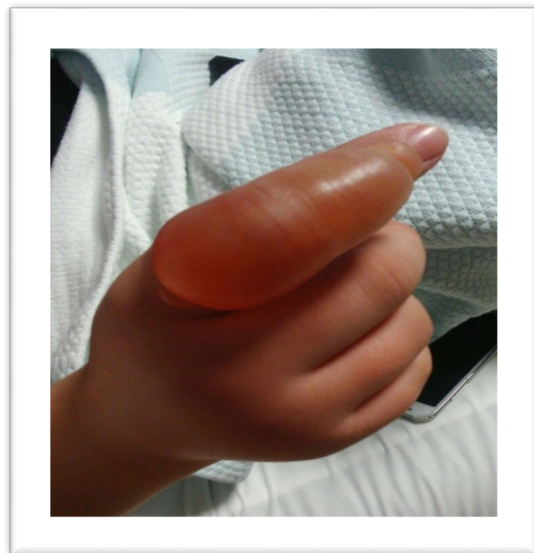- ✓ If you see a lionfish in the wild, just admire it from a safe distance.
- ✓ Do not try to capture this fish.
- ✓ Do not grab, touch or step on it when diving, swimming, or snorkelling.
- ✓ Wear protective gloves or clothes that cover all exposed skin.
- ✓ Please be calm and tell your accompanier that you are stung by the lionfish in case of accident.
- ✓ Be aware of life-threatening envenomation may occur. First aid, urgent transportation and cardiopulmonary support may be needed.
- ✓ Tetanus prophylaxis is must in all cases.
- ✓ Recovery can take place slowly and in a long time, so victims should be followed up.

### Case report

A 14-year old boy was admitted to hospital with severe pain, numbness, pallor and bleeding complaints and with a puncture wound on his right hand. He was on a sailing boat with his father and accidentally stung by lionfish after holding a speargun with a lionfish. The lionfish slid down from the top of harpoon and the boy accidentally touched to the spine of the fish. His complaints were severe pain and puncture wound on the 2nd finger of his right hand. The pain intensified in minutes and he immersed his hand into hot water for 20 minutes to relieve the pain. However, as the water-cooled the pain intensified again. After the boy was admitted to the emergency department at the hospital, physicians were sceptic about the lionfish envenomation and they misdiagnosed as snakebite. The family called us to confirm the diagnosis of lionfish envenomation. His complaints were erythema, edema and blister/bulla formation at the dorsum of the index finger (Figures 3, 4, 5). He was treated with hot water immersion, antibiotic, painkillers, antihistamine drug, wound care and he was hospitalized for a week. The wound healed completely (Figure 6).

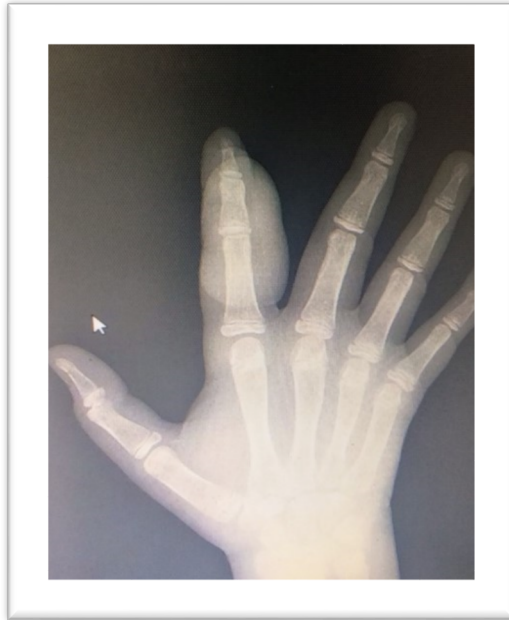


**Figure 3.** Sting site by lionfish. Puncture wound with local cyanosis, ecchymosis at the dorsum of the index finger after envenomation

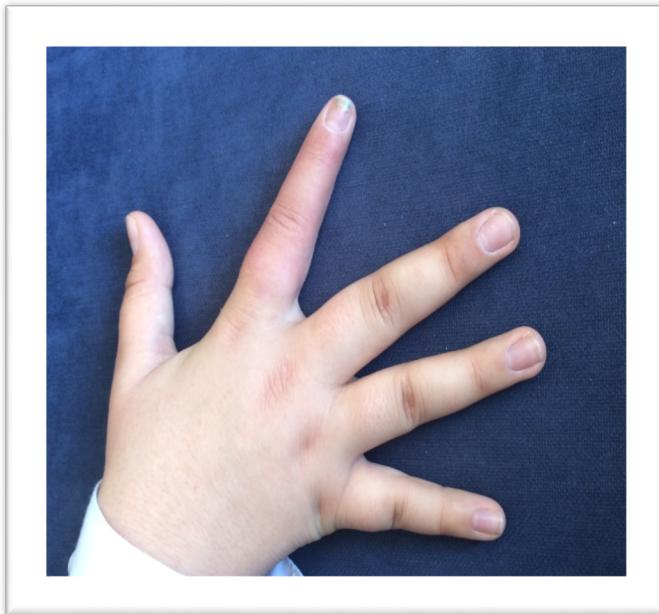

**Figure 4.** Sting site; Grade 2 wound with bullous lesion formation at the dorsum of the index finger





**Figure 5.** Radiologic imaging of the right hand. There was no spine or foreign body in the tissue



**Figure 6.** The wound healed without sequela after the treatment

## References

- Aktaş, Ş., Mirasoğlu, B. (2017) Lionfish envenomation: clinical aspect and management. *J. Black Sea/Mediterranean Environment* 23(1): 81-87.
- Alfredi, B., Ericksoni, T., Limpscomb, J. (1996) Lionfish envenomations in an urban wilderness. *Wilderness and Environmental Medicine* 4: 291-296.
- Atkinson, P.R.T., Boyle, A., Hartin, D., McAuley, D. (2006) Is hot water immersion an effective treatment for marine envenomation? *Emerg Med J* 23(7): 503-508.
- Auerbach, P.S. (1991) Marine envenomations. *N Engl J Med* 15: 486-493.
- Badillo, R.B., Banner, W., Morris, J.A., Schaeffer, S.E. (2011) A case study of lionfish sting-induced paralysis. *Aquaculture, Aquarium, Conservation & Legislation* 5(1): 1-3.
- Bariche, M., Kleitou, P., Kalogirou, S., Bernardi, G. (2017) Genetics reveal the identity and origin of the lionfish invasion in the Mediterranean Sea. Available at: [www.nature.com/scientificreports/7:6782/](http://www.nature.com/scientificreports/7:6782/) (accessed 20 Sep. 2018) doi: 10.1038/s41598-017-07326-1.
- Church, J.E., Hodgson, W.C. (2002) Adrenergic and cholinergic activity contributes to the cardiovascular effects of lionfish (*Pterois volitans*) venom. *Toxicon* 40: 787-779.
- Church, J.E., Moldrich, R.X., Beart, P.M., Hodgson, W.C. (2003) Modulation of intracellular Ca<sup>+2</sup> levels by Scorpaenidae venoms. *Toxicon* 41: 679-689.
- Cohen, A.S., Oleg, A.J. (1989) An extract of lionfish (*Pterois volitans*) spine tissue contains acetylcholine and a toxin that affects neuromuscular transmission. *Toxicon* 27:1367-1376.
- Courtenay, W.R. (1995) Marine fish introductions in southeastern Florida. *American Fisheries Society Introduced Fish Section Newsletter* 14(1): 2-3.
- De Haro, L., Pommier, P. (2003) Envenomation: a real risk of keeping exotic house pets. *Vet Hum Toxicol* 45(4): 214-6.
- Diaz, J.H. (2014) Skin and soft tissue infections following marine injuries and exposures in travellers. *J Travel Med* 21(3): 207-213.
- Diaz, J.H. (2015) Marine Scorpaenidae envenomation in travelers: Epidemiology, management, and prevention. *J Travel Med* 22(4): 251-258.

Diaz, J.H., Lopez, F.A. (2015) Skin, soft tissue and systemic bacterial infections following aquatic injuries and exposures. *Am J Med Sci* 349(3): 269-275.

Edmonds, C. (2002) Venomous marine animals. In: Diving and Subaquatic Medicine, Fourth Edition. (eds., Edmonds, C. Lowry, C., Pennefather, J., Walker, R.) Edward Arnold, London, pp. 335-351.

Forrester, M.B. (2008) Pattern of lionfish envenomations reported to Texas poison control centers, 1998-2006. *Toxicological & Environmental Chemistry* 90(2): 385-391.

Garyfallou, G.T., Madden, J.F. (1996) Lionfish envenomation. *Ann Emerg Med* 28(4): 456-7.

Golani, D., Sonin, O. (1992) New records of the Red Sea fishes, *Pterois miles* (Scorpaenidae) and *Pteragogus pelycus* (Labridae) from the eastern Mediterranean Sea. *Jpn J Ichthyol* 39(2): 167-169.

Haddad, V.Jr., Stolf, H.O., Risk, J.Y., França, F.O., Cardoso, J.L. (2015) Report of 15 injuries caused by lionfish (*Pterois volitans*) in aquarist in Brazil: a critical assessment of the severity of envenomations. *J Venom Anim Toxins Incl Trop Dis* 21: 8 doi: 10.1186/s40409-015-0007-x.

Hornbeak, K.B., Auerbach, P.S. (2017) Marine envenomation. *Emerg Med Clin N Am* 35: 321-337.

Fernandez, I., Valladolid, G., Varon, J., Sternbach G. (2011) Encounters with venomous sea-life. *The Journal of Emergency Medicine* 40 (1):103-112.

Jung Hanss, T., Bodio, M. (2006) Medically important venomous animals: Biology, prevention, first aid, and clinical management. *Clinical Infectious Diseases* 43: 1309-1317.

Kizer, K.W., McKinney, H.E., Auerbach, P.S. (1985) Scorpaenidae envenomation. A five- year poison center experience. *JAMA* 253(6): 807-10.

Maclsaac, H.J., De Roy, E.M., Leung, B., Grgicak-Mannion, A., Ruiz, G.M. (2016) Possible ballast water transfer of lionfish to the eastern Pacific Ocean. *PLoS One* 11: e0165584.

Por, F.D. (1971) One hundred years of the Suez Canal-a century of Lessepsian migration: Retrospects and viewpoints. *Syst Zool* 20(2): 138-195.

Resiere, D., Cerland, L., De Haro, L., Valentino, R., Criquet-Hayot, A., Chabartier, C., Kaidomar, S., Brouste, Y., Mégarbane, B., Mehdaoui, H. (2016)

Envenomation by the invasive *Pterois volitans* species (lionfish) in the French West Indies--a two-year prospective study in Martinique. *Clin Toxicol (Phila)* 54(4): 313-318.

Ruiz-Carus, R., Matheson, R.E., Roberts, D.E., Whitfield, P.E. (2006) The western Pacific red lionfish, *Pterois volitans* (Scorpaenidae), in Florida: Evidence for reproduction and parasitism in the first exotic marine fish established in state waters. *Biological Conservation* 128: 384-390.

Schmitt, C., de Haro, L. (2013) Clinical marine toxicology: A European perspective for clinical toxicologists and poison centers. *Toxins* 5: 1343-1352.

Schult, R.F, Acquisto, N.M., Stair, C.K. Wiegand, T.J. (2017) A case of lionfish envenomation presenting to an inland emergency department. *Case Reports in Emergency Medicine* doi: 10.1155/2017/5893563.

Trestrail, J.H., al-Mahasneh, Q.M. (1989) Lionfish string experiences of an inland poison center: a retrospective study of 23 cases. *Vet Hum Toxicol* 31(2): 173-175.

Turan, C., Ergüden, D., Gürlek, M., Yağlıoğlu, D., Uyan, A., Uygur, N. (2014) First record of the Indo-Pacific lionfish *Pterois miles* (Bennett, 1828) (Osteichthyes: Scorpaenidae) for the Turkish marine waters. *J Black Sea/Medit Environ* 20(2): 158-163.

Turan, C., Öztürk, B. (2015) First record of the lionfish *Pterois miles* (Bennett 1828) from the Aegean Sea. *J Black Sea/Medit Environ* 21(3): 334-338.

Vetrano, S.J., Lebowitz, J.B., Marcus, S. (2002) Lionfish envenomation. *J Emerg Med* 23(4): 379-382.

Zelaya, M.A.M. (2012) Toxic effects and management of injuries caused by the lion fish (*Pterois volitans*, *P. miles*). *Rev Fac Cienc Méd* 9-17.

Zenetos, A., Gofas, S., Morri, C., Rosso, A., Violanti, D., Garcia Raso, J.E., Çınar, M.E., Almogi-Labin, A., Ates, A.S., Azzurro, E., Ballesteros, E., Bianchi, C.N., Bilecenoğlu, M., Gambi, M.C., Giangrande, A., Gravili, C., Hyams-Kaphzan, O., Karachle, P.K., Katsanevakis, S., Lipej, L., Mastrototaro, F., Mineur, F., Pancucci-Papadopoulou, M.A., Ramos Espla, A., Salas, C., San Martin, G., Sfriso, A., Streftaris, N., Verlaque, M. (2012) Alien species in the Mediterranean Sea by 2012. A contribution to the application of European Union's Marine Strategy Framework Directive (MSFD). Part 2. Introduction trends and pathways. *Mediterr Mar Sci* 13: 328-352.