



Cone-beam computed tomography evaluation of impacted and transmigrated mandibular canines: a retrospective study

Hulya Cakir Karabas¹ · Ilknur Ozcan¹ · Ahmet Faruk Erturk¹ · Beliz Guray¹ · Gurkan Unsal² · Sukriye Neslihan Senel¹

Received: 30 April 2020 / Accepted: 30 June 2020

© Japanese Society for Oral and Maxillofacial Radiology and Springer Nature Singapore Pte Ltd. 2020

Abstract

Objectives The purpose of this study is to evaluate CBCT images of impacted mandibular canines in detail and to discuss implications for diagnosis and treatment.

Methods CBCT images of dental patients applied between December 2015 and December 2017 were evaluated retrospectively. 2591 CBCT images, including mandible in their field of view, were determined and evaluated regarding the presence of mandibular canine impaction. 66 impacted mandibular canines of 58 patients were analyzed in detail regarding their location, morphology, associated pathologies, and their relationship with the neighboring anatomic structures, the role of these factors on transmigration, as well as treatments applied. The Pearson Chi square test was used between the groups.

Results Transmigration was observed in 53% of impacted mandibular canines. Teeth with transmigration were localized horizontally, below the apex of adjacent teeth frequently, and had no contact with mandibular cortical bone mostly. 62% of mandibular canines were in contact/proximity with the incisive mandibular canal. The most applied treatment for transmigrated teeth was surgical removal, followed by radiographic monitoring, but orthodontic traction was not preferred in any case. For non-transmigrated teeth, the most applied treatment options were surgical removal, orthodontic traction, and radiographic monitoring, respectively. Autotransplantation was not preferred in any case of impacted teeth. Vertical position of the crown tip ($p < 0.05$) and the presence of deciduous mandibular canines and their resorption showed significant relation to transmigration ($p < 0.05$).

Conclusion Transmigration is common among impacted mandibular canines. Resorption of adjacent teeth roots was one of the possible complications of impaction and likely contact/proximity of incisive mandibular canal with impacted mandibular canines, which may pose difficulties in surgical treatment, can be better detected by CBCT.

Keywords Cone beam computed tomography · Impacted canine · Mandibular canine · Transmigration

Introduction

The presence of maxillary and mandibular canines in their normal position is important in terms of esthetics and functionality [1]. Impacted permanent canines are one of the frequently reported dental anomalies in the literature [2]. Mandibular canine impaction is very rare, with an incidence ranging between 0.92 and 1.35%. On the other side,

maxillary canine impaction is seen 20 times higher than mandibular canine impaction with an incidence of 0.8–2.8% [2–5].

Although migration of teeth is a well-defined phenomenon in the literature, dental transmigration, known as intra-osseous migration of unerupted teeth across the midline, has been rarely reported [5, 6]. Previously, transmigration had been associated with only mandibular canine teeth, but, a few cases of transmigrated maxillary canines have been reported recently [7–9]. Although transmigration is more common in the mandible, its incidence is also rarely ranging from 0.1 to 0.31% [3, 4]. Transmigration seems to be more common in males than females and to occur more often on the right side of the jaws than on the left side [2, 10].

Despite having an unknown etiology, it is believed that both genetic and epigenetic factors affect migration; local

✉ Hulya Cakir Karabas
hulya.cakirkarabas@gmail.com

¹ Department of Dentomaxillofacial Radiology, Faculty of Dentistry, Istanbul University, Capa/Fatih, 34093 Istanbul, Turkey

² Department of Dentomaxillofacial Radiology, Faculty of Dentistry, Near East University, Nicosia, Cyprus

factors preventing normal eruption are the primary cause. Its etiology includes trauma, early loss, and persistence of deciduous teeth, filling of the canine space by an adjacent tooth, shape anomalies of adjacent teeth, cysts, and tumours [2, 4, 10–14].

In the previous studies and dental practices, conventional two-dimensional (2D) methods (periapical radiographs, orthopantomographs, occlusal radiographs, lateral cephalograms and posteroanterior views) had been mainly used for the diagnosis of impacted canines [15]. Three-dimensional (3D) methods, multi-detector raw computed tomography (CT) and cone beam computed tomography (CBCT) have been considered more effective diagnostic tools since they may help to determine the position of the impacted canines more precisely and to give more insight into adjacent roots, root resorptions and calcific metamorphosis [16].

This study aims to evaluate the impacted mandibular canines' localization, morphology, associated pathologies and their relationships with anatomic structures such as mental foramen and incisive mandibular canal, the role of these factors on transmigrating, as well as treatments applied, and to discuss implications for diagnosis and treatment of impaction and transmigrating.

Materials and methods

This study was conducted at Istanbul University, Faculty of Dentistry, Department of Dentomaxillofacial Radiology, and the protocol was approved by the Clinical Research Ethics Committee of the Faculty of Dentistry, Istanbul University, Turkey (Protocol number: 2017/83). Out of the

archive images taken by the Department between December 2015 and December 2017, 2591 CBCT cases, including mandible in their field of view, were determined and evaluated concerning mandibular canine impaction by two dental radiologists and two doctorate students. Afterward, 66 canine cases of 58 patients were evaluated in detail by a single dental radiologist.

CBCT images were acquired by Scanora 3D-X CBCT Unit by Soredex (Tuusula, Finland) with 0.1–0.3 mm slice thickness, 60–90 kV, 4–10 mA, 18–34 s scan time, 50 × 50–180 × 165 mm field of view. The stored DICOM files were transferred to a working station, and multiplanar reconstructions were generated using a dental software named OnDemand3D™ by Cybermed (California, USA).

The following eight parameters were used to evaluate the impacted mandibular canines:

1. Mandibular cortical bone and impacted canine's apex relation: The relation between these two structures were divided into four groups as [4] (Fig. 1):

Type 1—There is no contact between the two structures.

Type 2—The impacted canine is in contact with the mandibular labial cortical plate.

Type 3—The impacted canine is in contact with the mandibular cortical plate's basal.

Type 4—The impacted canine is in contact with the mandibular lingual cortical plate.

2. Mental foramen and impacted canine's relation: The relation between these two structures were divided into two groups as:

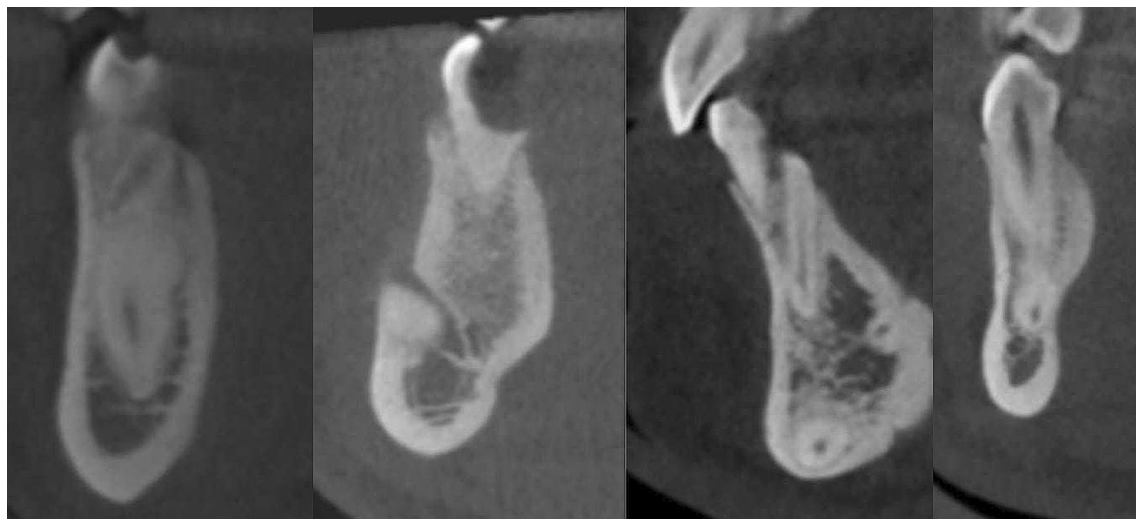

Fig. 1 Mandibular cortical bone and impacted canine's apex relation: **a** There is no contact between two structures. **b** The impacted canine is in contact with mandibular labial cortical plate. **c** The impacted

canine is in contact with mandibular cortical plate's basal. **d** The impacted canine is in contact with mandibular lingual cortical plate

Type 1—The impacted canine is in contact with the mental foramen.

Type 2—The impacted canine is not in contact with the mental foramen.

3. Incisive mandibular canal and impacted canine's relation: the relation between these two structures were divided into four groups as:

Type 1—There is no incisive mandibular canal.

Type 2—There is an incisive mandibular canal but the impacted canine is not in contact with that.

Type 3—There is an incisive mandibular canal and the impacted canine is in contact with that.

Type 4—The incisive mandibular canal is not in the field of view.

4. Transmigrated canines were divided into five groups according to their positions [6]:

Type 1—Impacted canines that were positioned across the midline of the relevant jaw in a mesio-angular position, lingual or labial to incisor teeth with its crown crossing the midline.

Type 2—Impacted canines that were positioned at the inferior of incisor teeth horizontally, near the mandibular basis.

Type 3—Impacted canines that were positioned at the mesial or distal of the opposite canine.

Type 4—Impacted canines that were positioned at the inferior of mandibular premolars or molars horizontally, near the mandibular basis on the opposite side.

Type 5—Impacted canines that were positioned vertically in the midline.

5. Impacted canines were divided into groups according to their histopathological diagnosis [17].
6. Severities of root resorptions at the neighbor teeth were divided into four groups [4, 18, 19]:

Type 1—Intact root surface without resorption.

Type 2—Root resorption, which extends to the half of the dentine.

Type 3—Root resorption, which extends to more than half of the dentine.

Type 4—Root resorption with exposed pulp.

7. A frontal plane through the mandibular midline, as Bertl et al. designed, was used to classify the angulation and distance to the midline. The shortest distance between the canine tip and the plane was measured. Transmigrated canines were valued as negative, while 0° used to define vertical, coronally angulation, and 90° for horizontal, mesially angulation. Negative values were used to define distally directed angulation [4].

8. Impacted canines were divided into four groups according to the treatment/follow up that was performed:

Type 1—Impacted canines that were treated with orthodontic treatment.

Type 2—Impacted canines that were extracted.

Type 3—Impacted canines that were used for autotransplantation.

Type 4—Impacted canines that had been monitored.

All statistical analyses were performed using statistical software SPSS version 21.0 (IBM Corp, Inc, New York, USA). Data were described with frequencies and percentages for categorical data and with median, minimum, maximum and quartiles for continuous data. Associations between two categorical covariates were tested by the Pearson Chi square test. Kolmogorov–Smirnov test was used to test the normality of continuous data. Independent-samples *t* test and Mann–Whitney *U* test were used to compare differences between two independent groups when the dependent variable is either ordinal or continuous, but not normally distributed. Differences were considered statistically significant when *p* values were ≤ 0.05 .

Results

In our retrospective study, CBCT images of 58 patients (30 (51.7%) male, 28 (48.3%) female) including 66 impacted mandibular canines (i.e. bilateral mandibular canine impaction was present in eight cases (13.8%)) were evaluated. 32 patients had transmigrated impacted mandibular canine (14 males (43.7%), 18 females (56.3%)), whereas 26 patients had only impacted mandibular canine (16 males (61.5%), 10 females (38.5%)). The age of the patients at the time of CBCT imaging ranged from 12 to 65 years (mean age 26.0 years).

Impacted mandibular canine crowns were mainly located centrally (21 non-transmigrated (67.8%), 14 transmigrated (40%)). This factor showed a significant relation to transmigration ($p < 0.05$) (Table 1).

With regards to vertical position, the crown tip of most transmigrated canines (62.90%) was located below the apex of adjacent teeth, whereas the crown tip of non-transmigrated canines mainly (45.20%) was located at the height of middle third of adjacent roots. No transmigrated canines were found at the height of the cervical third of adjacent root and above CEJ. Besides, it was not found any non-transmigrated canines below the apex of adjacent teeth. Vertical position of the crown tip in both groups showed a significant relation to transmigration ($p < 0.05$) (Table 1).

More than half of mandibular canines' apex had no contact with the mandibular cortical bone (59.09%). Contact with mandibular cortical bone showed no significant relation to transmigration ($p > 0.05$) (Table 1).

Although, in most cases, there was no contact of the mandibular canine with the mental foramen, 6 cases of transmigrated canines (17.10%) and 3 cases of non-transmigrated

Table 1 Summary of the results

| | | Transmigrated | Non-transmigrated | <i>p</i> < 0.05 |
|---|--|---------------|-------------------|---------------------------------------|
| Labio-lingual position of the mandibular canine's crown | Labially impacted | 11 (31.40%) | 5 (16.1%) | <i>p</i> = 0.044 |
| | Centrally impacted | 14 (40.00%) | 21 (67.8%) | |
| | Lingually impacted | 3 (8.60%) | 4 (12.9%) | |
| | Oblique | 7 (20.00%) | 1 (3.2%) | |
| Vertical position of the mandibular canine's cusp tip | Below apex of adjacent teeth | 22 (62.90%) | 0 (0.00%) | <i>p</i> = 0.000 |
| | Apical 1/3 of adjacent roots | 8 (22.90%) | 9 (29.00%) | |
| | Middle 1/3 of adjacent roots | 5 (14.30%) | 14 (45.20%) | |
| | Cervical 1/3 of adjacent roots | 0 (0.00%) | 7 (22.60%) | |
| | Above CEJ of adjacent teeth | 0 (0.00%) | 1 (3.20%) | |
| Contact of the canine's apex with the mandibular cortical bone | No contact | 21 (60.0%) | 18 (58.06%) | <i>ns</i> (<i>p</i> = 0.491) |
| | Labial contact | 4 (11.4%) | 1 (3.2%) | |
| | Lingual contact | 2 (5.7%) | 5 (16.1%) | |
| | Basal contact | 8(22.90%) | 7 (22.5%) | |
| Contact of the mandibular canine with the mental foramen | Contact | 6 (17.10%) | 3 (9.70%) | <i>ns</i> (<i>p</i> = 0.378) |
| | No contact | 29 (82.90%) | 28 (90.30%) | |
| Contact of the mandibular canine with the incisive mandibular canal | No canal | 6 (17.10%) | 8 (25.80%) | <i>ns</i> (<i>p</i> = 0.380) |
| | Canal with no contact to canine | 6 (17.10%) | 3 (9.70%) | |
| | Canal with contact/proximity to canine | 21 (60.00%) | 20 (64.50%) | |
| | No visualization of canal | 2 (5.70%) | 0 (0.00%) | |
| Mupparapu classification of transmigrated canine teeth | Excluded (Bilateral teeth) | 4 (11.40%) | | <i>p</i> = 0.000 |
| | Type 1 | 6 (17.10%) | | |
| | Type 2 | 16 (45.70%) | non applicable | |
| | Type 3 | 4 (11.40%) | | |
| | Type 4 | 4 (11.40%) | | |
| | Type 5 | 1 (2.80%) | | |
| Root resorptions of adjacent teeth | Type 1: No resorption | 29 (82.90%) | 25 (80.60%) | <i>ns</i> (<i>p</i> = 0.365) |
| | Type 2: Slight resorption | 5 (14.30%) | 4 (12.90%) | |
| | Type 3: Moderate resorption | 0 (0.00%) | 2 (6.50%) | |
| | Type 4: Severe resorption | 1 (2.90%) | 0 (0.00%) | |
| Development of the root of the impacted canine | ½ of the root length developed | 1 (2.90%) | 0 (0.00%) | <i>ns</i> (<i>p</i> = 0.530) |
| | ¾ of the root length developed | 1 (2.90%) | 0 (0.00%) | |
| | Complete, Wide-open apex | 0 (0.00%) | 1 (3.20%) | |
| | Complete, Half-closed apex | 2 (5.70%) | 1 (3.20%) | |
| | Complete, Closed apex | 31 (88.60%) | 29 (93.50%) | |
| The status and resorption the deciduous mandibular canines | Missing | 15 (42.90%) | 13 (41.90%) | <i>p</i> = 0.001 |
| | No contact, No resorption | 1 (2.90%) | 0 (0.00%) | |
| | Contact, No resorption | 1 (2.90%) | 0 (0.00%) | |
| | No contact, Resorption | 18 (51.40%) | 6 (19.40%) | |
| | Contact, Resorption | 0 (0.00%) | 12 (38.70%) | |
| Resorptions | Yes | 5 (14.30%) | 5 (16.10%) | <i>ns</i> (<i>p</i> = 0.835) |
| | No | 30 (85.70%) | 26 (83.90%) | |
| Apical dilacerations | Yes | 8 (22.90%) | 7 (22.60%) | <i>ns</i> (<i>p</i> = 0.979) |
| | No | 27 (77.10%) | 24 (77.40%) | |
| The stage of eruption | Not erupted | 16 (45.70%) | 18 (58.10%) | <i>p</i> = 0.000 |
| | Labially erupted | 18 (51.40%) | 2 (6.50%) | |
| | Crestally erupted | 0 (0.00%) | 8 (25.80%) | |
| | Lingually erupted | 1 (2.90%) | 3 (9.70%) | |

canines (9.70%) revealed contact with the mental foramen (Table 1).

60.00% of transmigrated and 64.50% of non-transmigrated canines had contact with or were proximate to the incisive mandibular canal, which was found in most cases. It was not found only in 6 cases of transmigrated canines (17.10%) and in 8 cases of non-transmigrated canines (25.80%) (Table 1).

Transmigrated mandibular canines were evaluated according to Mupparapu classification; 2 bilateral transmigrated teeth were excluded from the study. The majority of the related teeth were classified as type 2 (45.70%) (Table 1).

The pathologic lesions associated with impacted mandibular teeth were observed as follows (Table 2). Odontoma (7 transmigrated), dentigerous cyst (1 transmigrated, 1 non-transmigrated), adenomatoid odontogenic tumor (1 non-transmigrated), odontogenic keratocyst (2 transmigrated) (Fig. 2). Hyperplastic dental follicle was found in 18 patients (17 transmigrated, 1 non-transmigrated). Supernumerary teeth associated with impacted mandibular teeth were observed in 1 transmigrated and 2 non-transmigrated mandibular canine teeth.

Although we mostly observed no root resorptions of adjacent teeth (29 cases in transmigrated (82.90%) and 25 cases in non-transmigrated canines (80.60%)), resorption was observed in twelve impacted canines (18.18%) including only one severe resorption in transmigrated canine. Root development was completed nearly at all canines (96.96%) with closed apex in most cases (90.90%). Resorption of the impacted canine was observed in ten cases (15.15%). 15 canines (22.72%) showed apical dilacerations of the root. All these 4 findings showed no significant relation to transmigration ($p > 0.05$) (Table 1).

Regarding the status and resorption of the deciduous mandibular canines, in nearly half of the cases (42.42%), these teeth were missing. On the other side, although there was no contact, resorption was observed in 51.40% of transmigrated canines. Impacted (non-transmigrated) canines were either missing (41.90%) or having resorption. The presence of deciduous mandibular canines and their resorption showed significant relation to transmigration ($p < 0.05$) (Table 1).

More than half of the impacted mandibular canines (51.51%) did not erupt. Transmigrated canines were labially erupted in most cases (51.40%), whereas non-transmigrated ones were mainly unerupted (58.10%) and crestally erupted (25.80%) in case they erupted. Eruption showed significant relation to transmigration ($p < 0.05$) (Table 1).

The distance of the canine’s crown tip to the midline was observed in a range between 0 and – 27.06 mm with a mean value of – 11.68 mm for transmigrated teeth, and between 2.66 and 14.77 mm with a mean value of 8.52 mm for non-transmigrated teeth. The distance of the canine’s crown tip to the midline showed a significant relation to transmigration ($p < 0.05$).

Angulation to a sagittal plane ranged from 0° to 90° with a mean of 71.78° for transmigrated teeth, and 0° to 90° with a mean of 18.59° for non-transmigrated teeth. Angulation to a sagittal plane showed a significant relation to transmigration ($p < 0.05$).

Table 2 The pathologic lesions associated with impacted mandibular teeth

| Demographic data | | Transmigration | | Pathology | | | |
|------------------|--------|----------------|-------------------|-----------|------------------|------------------------|--------------------------------|
| Age | Gender | Transmigrated | Non-transmigrated | Odontoma | Dentigerous Cyst | Odontogenic keratocyst | Adenomatoid odontogenic tumour |
| 12 | M | X | | | X | | |
| 12 | M | X | | | | X | |
| 16 | F | X | | X | | | |
| 17 | M | X | | X | | | |
| 18 | F | X | | X | | | |
| 19 | F | X | | X | | | |
| 24 | F | X | | X | | | |
| 37 | M | X | | X | | | |
| 41 | M | X | | X | | | |
| 51 | M | X | | | | X | |
| 21 | M | | X | | | | X |
| 65 | M | | X | | X | | |

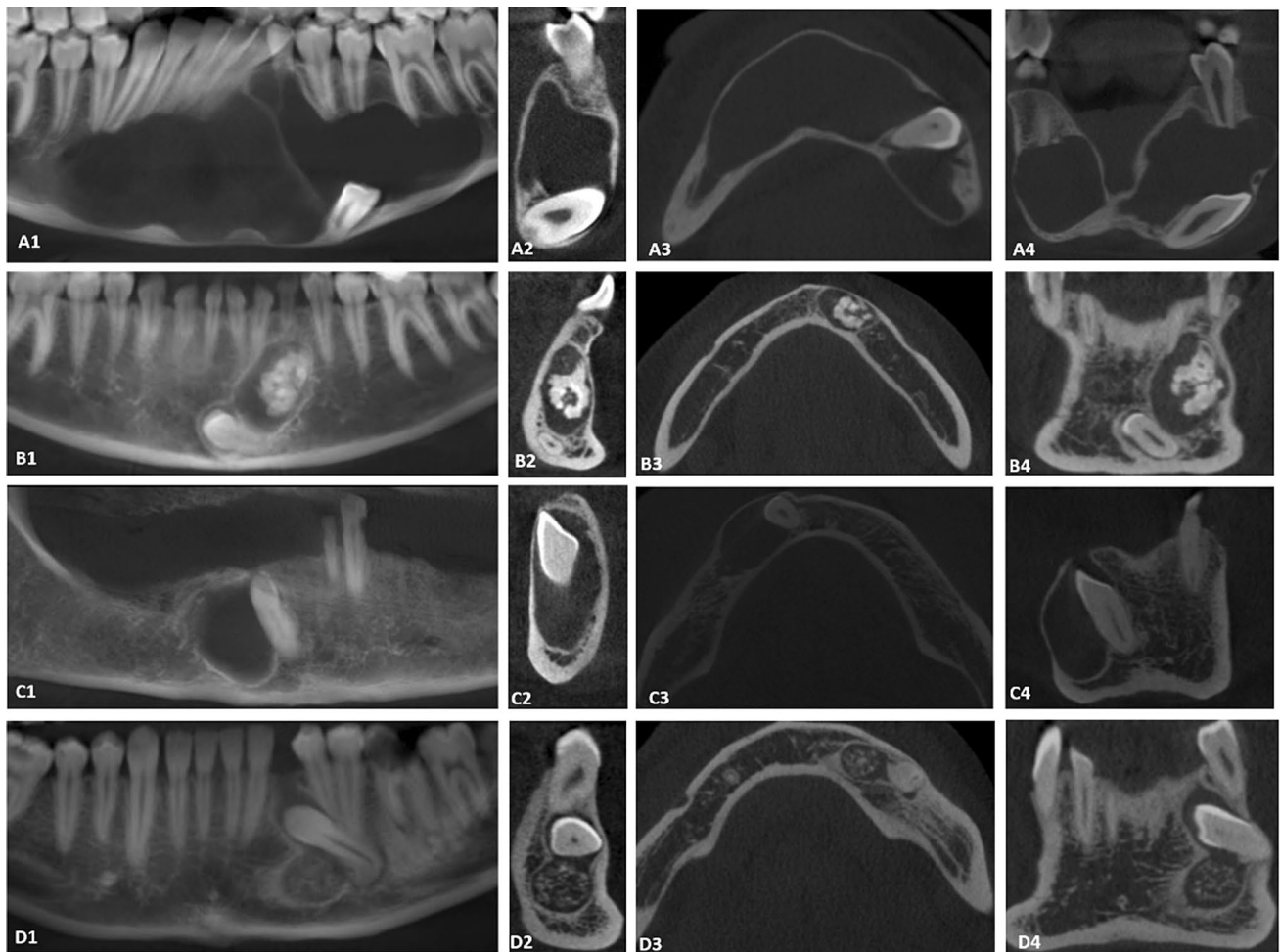


Fig. 2 CBCT panoramic reconstruction, CBCT cross-sectional images, CBCT axial slices and CBCT coronal slices of 4 pathologies associated with impacted (both transmigrated and non-transmigrated) canines, were seen. Associated pathologies were odontogenic keratocyst, compound odontoma, dentigerous cyst and adenomatoid odontogenic tumour. **a** Odontogenic keratocyst. A multilocular hypodense lesion with well-defined scalloped borders which caused expansion at buccal cortical plate is seen. The lesion is extending along the internal aspect of the mandible. Note the impacted canine at mandibular

basis. **b** Compound odontoma. Multiple well-formed denticles with a well-defined cortical border is seen above the impacted canine. **c** Dentigerous cyst. Non-expansive, unilocular hypodense lesion attached to the cemento-enamel junction of the impacted canine is seen. **d** Adenomatoid odontogenic tumour. Non-expansive, unilocular mixed lesion with the follicle of the impacted canine is seen. Unlike the dentigerous cysts, the lesion is attached apical to the cemento-enamel junction and calcified hyperdense areas are present within the tumour mass

Discussion

Transmigration is a rare eruptive disorder that has been described as pre-eruptive migration of an affected canine across the midline. Across the midline phrase is the most important term to define transmigration and it has been interpreted differently in the literature: some argued that one half or more of the length of the tooth was required to cross the midline, while others lined up with the idea that it is not the distance but crossing the midline is important for defining the transmigration, without defining the length to cross [16, 20]. Defining the midline has been problematic in conventional radiography since cranial landmarks have been

used to define mandibular midline, but mandible is a moving part. CBCT enables anatomical landmarks to be used for defining the midline more precisely [4].

We analyzed a large group of CBCT images of impacted mandibular canines in detail with regard to their location, morphology, adjacent anatomic structure, associated pathologies, and the relation of these factors with transmigration. 53.03% of impacted mandibular canines were transmigrated in our study.

The prevalence of labially impacted mandibular canines and lingually impacted mandibular canines were found different in different studies. Bertl et al. stated that, since they conducted the study with 3D imaging techniques, labially

impacted canines were found to occur more than sixfold of lingually impacted ones [4]. However, our study was done with a CBCT device and the labial–lingual impaction rate was disaccorded with Bertl et al.'s study. Unlikely, the central impaction type was the most observed in our study.

Age is a crucial factor in transmigration. The reported age of patients in the literature varies between 8 and 69 years, which also coincides with the ages of our patients (12–65 years). Transmigration most likely occurs during canine formation, which starts at the age of 3 months and is completed when the mandibular canine root is completed at 13.2 years for boys and 11.5 years for girls. Much of the movement of the tooth takes place before root development; therefore, it is suggested to undergo clinical and radiological examination between 8 and 9 years old [16, 21, 22]. Since the minimum age of included patients in our study is 12 years, in more than 90% of the cases, development of root of the impacted canine was completed with closed apex.

Mupparapu ranked the most common types of transmigration as type 1, type 2, type 4, type 3 and type 5 [6]. In the study of Bertl et al., the most common was type 1 followed by type 2, type 3/type 5 [4]. In a study of the Turkish population, type 2 was the most common, followed by type 1 and type 3 [2]. In our study, type 2 was the most common followed by type 1, type 3/type 4 and type 5. Sample sizes may lead to different results.

A canine is considered to have a normal angulation if it is between 0° and 25° . Impacted canines which have axial inclination between 30° and 95° tend to cross the midline, but if the angulation is more than 50° , they cross the midline [9, 21, 23].

It has been reported that horizontally angulated canines were most likely to transmigrate [4]. This observation was also observed in our study. The most common type of transmigration was type 2 and the mean angulation of the transmigrated canines was 71.78° .

Canines of which apex is in contact with the mandibular cortical bone are unlikely to transmigrate since cortical bone is dense and more resilient to resorption [4, 24]. Our study also supported this tendency with 60% of transmigrated canines having no contact with the mandibular cortical bone.

Transmigration often occurs during the root development process; thus, apical dilacerations seem not to prevent transmigration since they develop after transmigration. We observed 8 canines out of 35, which had apical dilacerations.

Late diagnosis of impacted canines may result in root resorption of adjacent teeth. Although the incidence of root resorption of adjacent teeth in impacted maxillary canines has been reported relatively high in the literature, especially with the use of CT and CBCT which enables two-fold detection of root resorptions compared to 2D imaging, the rate of root resorption of adjacent teeth in impacted mandibular canines needs to be considered [25, 26]. In our study, it was

observed root resorption of adjacent teeth in 12 cases out of 66 teeth. Therefore, it should be considered, especially in the planning of dental treatment.

Retention of primary canine implies most likely the case of impaction or transmigration of the permanent canine as agenesis of the permanent canine is rare [2]. In our study, 57.58% of patients had primary canines.

The mandibular incisive nerve is described as the terminal branches of the inferior alveolar nerve that continues its intraosseous pathway into the mandibular anterior region through the mental foramen. The mandibular incisive canal (MIC), in which the incisive nerve runs through, is located mesially to the mental foramen, smaller in diameter and less corticalized than the mandibular canal. Since MIC is less corticalized, and the incisive nerve is running through intramedullary spaces, it is hard to detect MIC by conventional radiography [27]. Studies in the literature reveal that MIC can be detected in 15% of the cases by panoramic radiography, whereas CT can detect MIC in 93% of the cases. CBCT provides more visibility in detecting MIC [28]. In our study, the presence of MIC was visualized by CBCT in 50 (75.76%) cases of impacted mandibular canine teeth. In 41 (62.12%) CBCT images, MIC was observed in contact/proximity with impacted mandibular canines. In the mental interforaminal region, which is generally considered as a safe region, the presence of MIC can pose important risks for surgical procedures such as sensory disturbances, edema, hematoma and lack of osseointegration of implants, pulp sensitivity changes. In this regard, to reduce postoperative complications, usage of CBCT is significant for the success of surgical procedures [27, 29].

The mental foramen (MF), through which the mental nerve and blood vessels emerge, is located between the mandibular premolars or apical to the second premolar. To avoid sensory dysfunction or paresthesia due to mental nerve injury, the detection of presence and location of MF is crucial to the success of the surgery, and CBCT can be very useful in this regard [30, 31]. In our study, contact with the MF was seen in 9 (13.64%) cases of mandibular canine impaction.

Despite various theories trying to describe the etiology of transmigration, and several factors such as trauma, heredity, premature loss of deciduous teeth, tumors, and cysts, the mechanism has not been clear yet [2, 3, 9]. Besides, it has been hard to decide whether pathological conditions cause transmigration or transmigration leads to pathologies. Seven odontomas, two odontogenic keratocysts, and one dentigerous cyst were found to be associated with ten transmigrated canines. 25 out of 35 transmigrated canines were not associated with any pathological lesion.

Odontomas usually interfere with the anatomical eruption of teeth. It has been reported that 70% of the odontomas are associated with impaction, diastema, malformation,

malpositioning, aplasia, and devitalization of adjacent teeth; thus, it was expected that the most common pathology among the transmigrated impacted canine would be odontomas [17]. Dentigerous cyst generally displaces the associated teeth in an apical direction at various degrees, and occasionally they can cause transmigrations [17]. Odontogenic keratocysts characteristically grow along the trabecular aspect of the jaws and cause minimal expansion. Odontogenic keratocysts can also displace the impacted teeth [17]; however, we were unable to find any mandibular transmigrated canine report, which was associated with an odontogenic keratocyst in the literature.

Transmigration being mainly asymptomatic, it is often diagnosed incidentally in clinical examination. When transmigration occurs near the midline or on the opposite side of the arch, it may result in pain from inflammation or infection [9]. The treatment strategies include orthodontic traction, autotransplantation, surgical removal of non-transmigrated impacted canines; orthodontic traction, autotransplantation, surgical removal and radiographic monitoring of transmigrated canines. Clinical and radiological findings should be carefully considered in treatment planning [1–3, 5]. Especially when surgical removal is required, it is suggested to be aware of the fact that the transmigrated teeth provide their nerve supply from the original side [1]. In our study, the most applied treatment for transmigrated teeth was surgical removal (64.71%), followed by radiographic monitoring (34.2%); and it was surgical removal (69.29%), orthodontic traction (29.03%) and radiographic monitoring for non-transmigrated teeth. As seen in both groups, surgical removal was the most applied treatment, which was mainly due to more severe clinical consequences of impacted teeth. Autotransplantation was not preferred in any case of impacted teeth.

Conclusion

- Transmigration is common among impacted mandibular canines. Likely, indicators of transmigration include axial inclination of impacted canines and retention of deciduous mandibular canines.
- In the case of impacted mandibular canines, root resorption of adjacent teeth is one of the possible complications; and CBCT can better detect root resorption compared to 2D imaging.
- Likely contact/proximity of incisive mandibular canal with impacted mandibular canines may pose difficulties in surgical treatment. CBCT can better observe the presence of contact/proximity.
- For early diagnosis and better treatment, it is recommended to undergo a clinical and radiological examination 2–3 years before 12 years old.

Acknowledgements No external or internal funding was required since the study was a retrospective study using the archives of the Department of Oral and Maxillofacial Radiology. Authors thank to the Department of Tumor Pathology, Institute of Oncology, Istanbul University for their valuable contribution.

Compliance with ethical standards

Human rights statements and informed consent/Animal rights statements This article does not contain any studies with human or animal subjects performed by the any of the authors.

Conflict of interest Author Hülya ÇAKIR KARABAŞ, Author İlknur ÖZCAN, Author Ahmet Faruk ERTÜRK, Author Beliz GÜRAY, Author Gürkan Ünsal, and Author Şükriye Neslihan ŞENEL declare that they have no conflict of interest.

References

1. Buyukurt MC, et al. Transmigrant mandibular canines. *J Oral Maxillofac Surg.* 2007;65(10):2025–9.
2. Gunduz K, Celenk P. The incidence of impacted transmigrant canines: a retrospective study. *Oral Radiol.* 2010;26:77–81.
3. Dalessandri D, et al. Impacted and transmigrant mandibular canines incidence, aetiology, and treatment: a systematic review. *Eur J Orthod.* 2017;39(2):161–9.
4. Bertl MH, et al. Impacted and transmigrated mandibular canines: an analysis of 3D radiographic imaging data. *Clin Oral Investig.* 2018;22(6):2389–99.
5. Bhullar MK, et al. Mandibular canine transmigration: report of three cases and literature review. *J Int Soc Prev Commun Dent.* 2017;7(1):8–14.
6. Mupparapu M. Editorial: medication-related osteonecrosis of the jaw (MRONJ): Bisphosphonates, antiresorptives, and antiangiogenic agents What next? *Quintessence Int.* 2016;47(1):7–8.
7. Celikoglu M, Kamak H, Oktay H. Investigation of transmigrated and impacted maxillary and mandibular canine teeth in an orthodontic patient population. *J Oral Maxillofac Surg.* 2010;68(5):1001–6.
8. Shastri D, Singh GP, Tandon P. Management of a patient with impacted maxillary canine, peg-shaped lateral incisors and transmigrated mandibular canine: a case report. *Int J Orthod Milwaukee.* 2016;27(3):15–8.
9. Aydin U, Yilmaz HH, Yildirim D. Incidence of canine impaction and transmigration in a patient population. *Dentomaxillofac Radiol.* 2004;33(3):164–9.
10. Sharma G, Nagpal A. A study of transmigrated canine in an indian population. *Int Sch Res Notices.* 2014;2014:756516.
11. Verma SL, Sharma VP, Singh GP. Management of a transmigrated mandibular canine. *J Orthod Sci.* 2012;1(1):23–8.
12. Sharma G, Nagpal A. Transmigration of mandibular canine: report of four cases and review of literature. *Case Rep Dent.* 2011;2011:381382.
13. Cavuoti S, et al. Combined orthodontic-surgical management of a transmigrated mandibular canine. *Angle Orthod.* 2016;86(4):681–91.
14. Plaza SP. Orthodontic traction of a transmigrated mandibular canine using mini-implant: a case report and review. *J Orthod.* 2016;43(4):314–21.
15. Kumar S, et al. Localization of impacted canines. *J Clin Diagn Res.* 2015;9(1):11–4.

16. Mazinis E, et al. Transmigration of impacted canines: prevalence, management and implications on tooth structure and pulp vitality of adjacent teeth. *Clin Oral Investig.* 2012;16(2):625–32.
17. White SC, Pharoah MJ. *Oral radiology: principles and interpretation.* 7th ed. New York: Elsevier Inc.; 2014. p. 679.
18. Strbac GD, et al. The prevalence of root resorption of maxillary incisors caused by impacted maxillary canines. *Clin Oral Investig.* 2013;17(2):553–64.
19. Lai CS, et al. Impacted maxillary canines and root resorptions of neighbouring teeth: a radiographic analysis using cone-beam computed tomography. *Eur J Orthod.* 2013;35(4):529–38.
20. Rozylo-Kalinowska I, et al. Transmigration of the left mandibular canine observed during 2 years in cone-beam computed tomography examination. *J Oral Maxillofac Radiol.* 2018;6(2):31–5.
21. Joshi MR. Transmigrant mandibular canines: a record of 28 cases and a retrospective review of the literature. *Angle Orthod.* 2001;71(1):12–22.
22. Hudson AP, Harris AM, Mohamed N. Early identification and management of mandibular canine ectopia. *SADJ.* 2011;66(10):462–6.
23. Howard RD. The anomalous mandibular canine. *Br J Orthod.* 1976;3(2):117–21.
24. Urias D, Mustafa FI. Anchorage control in bioprogressive vs straight-wire treatment. *Angle Orthod.* 2005;75(6):987–92.
25. Ericson SK. Incisor root resorptions due to ectopic maxillary canines imaged by computerized tomography: a comparative study in extracted teeth. *Angle Orthod.* 2000;70(4):276–83.
26. Alqerban A, et al. Comparison of two cone beam computed tomographic systems versus panoramic imaging for localization of impacted maxillary canines and detection of root resorption. *Eur J Orthod.* 2011;33(1):93–102.
27. Pereira-Maciel P, Tavares-de-Sousa E, Oliveira-Sales MA. The mandibular incisive canal and its anatomical relationships: a cone beam computed tomography study. *Med Oral Patol Oral Cir Bucal.* 2015;20(6):e723–8.
28. Gomes LT, et al. Anatomic evaluation of the incisive canal with cone beam computed tomography and its relevance to surgical procedures in the mental region: a retrospective study in a Brazilian population. *Oral Maxillofac Surg.* 2018;22(4):379–84.
29. Gilis S, et al. Mandibular incisive canal and lingual foramina characterization by cone-beam computed tomography. *Morphologie.* 2019;103(341):48–53.
30. Zmyslowska-Polakowska E, et al. Evaluation of size and location of a mental foramen in the polish population using cone-beam computed tomography. *Biomed Res Int.* 2019;2019:1659476.
31. da Silva Ramos LM, Capelozza AL, Rubira-Bullen IR. Absence and hypoplasia of the mental foramen detected in CBCT images: a case report. *Surg Radiol Anat.* 2011;33(8):731–4.

Publisher's Note Springer Nature remains neutral with regard to jurisdictional claims in published maps and institutional affiliations.